

Mandibular Movement Characteristics of an Anterior Disc Displacement with Reduction

James J.R. Huddleston Slater, DDS
Graduate Student

Frank Lobbezoo, DDS, PhD
Associate Professor

Machiel Naeije, PhD
Biophysicist and Professor

Department of Oral Function
Section Craniomandibular Disorders
Academic Centre for Dentistry
Amsterdam (ACTA)
Amsterdam
The Netherlands

Correspondence to:
Prof. Machiel Naeije
Department of Oral Function
Section Craniomandibular Disorders
Academic Centre for Dentistry
Amsterdam (ACTA)
Louwesweg 1
1066 EA Amsterdam
The Netherlands
Fax: +31 20 5188414
E-mail: m.naeije@acta.nl

Aims: According to the Research Diagnostic Criteria (*J Craniomandib Disord* 1992;6(4):301–355), an anterior disc displacement with reduction (ADD) is characterized by reciprocal clicking with the opening click occurring at a mouth opening at least 5 mm greater than that of the closing click. The aim of this study was to test whether the 5-mm criterion of the RDC is characteristic for a click due to an ADD. **Methods:** From 30 participants with a unilateral ADD, recordings of mandibular movements with 6 degrees of freedom as well as joint sound recordings were made. The participants performed free open movements and loaded closing movements. **Results:** In 8 joints (27%), the 5-mm criterion was not fulfilled. For 2 participants, the click while closing occurred with an even larger mouth opening than that while opening. Recordings of the condylar movements showed that the opening clicks occurred over a broad range of the opening movement, whereas all the closing clicks occurred just before the condyle reached its terminal position in the fossa. **Conclusion:** The 5-mm criterion of the RDC is not characteristic of all anterior disc displacements with reduction.

J OROFAC PAIN 2002;16:135–142.

Key words: temporomandibular joint, anterior disc displacement, clicking, condylar movements, recognition

Temporomandibular joint (TMJ) sounds are common symptoms of temporomandibular disorders. Epidemiological studies indicate that in a general population, the prevalence of these sounds ranges from about 15% to 40%.^{1–4} The more general term “sounds” embraces both clicks and crepitation. Clicking sounds are often due to an internal derangement within the TMJ, such as an anterior disc displacement with reduction (ADD) or a deviation in form (DIF). An ADD is described as a disc that is displaced from its position between the condyle and the eminence to an anterior position in maximum intercuspation, but that reduces (ie, restored condyle-disc relationship) on opening, usually resulting in a click.⁵

An ADD is generally considered a harmless disorder.⁶ However, this view is not undisputed, because according to some authors, an ADD may develop into a so-called closed lock.^{7,8} How often and under which conditions this occurs is unknown.^{9,10} Apart from this, the prevalence of an ADD is unknown, which might be due to the fact that clinically, the cause of TMJ clicking is difficult to establish. Notwithstanding these uncertainties, disc displacements

form 1 of the 3 main diagnostic subgroups of the research diagnostic criteria (RDC) for temporomandibular disorders.⁵ According to the RDC, 1 of the criteria for an ADD is reciprocal clicking on opening and closing “that occurs at a point at least 5 mm greater interincisal distance on opening than on closing and that is eliminated on protrusive opening.” Among others, this criterion was developed to enable the discrimination of an ADD from other clicks, like a DIF.¹¹

Measurements of the mouth opening at the time of clicking are probably used under the (silent) assumption that the amount of mouth opening is indicative of the condylar position at the time of clicking. However, it is known that the mouth opening is the net result of a large series of small, simultaneous translatory and rotatory movements of the mandible. The complex mixture of these components may vary within and between movements. For this reason it may be questioned whether the amount of mouth opening is indicative of the condylar position. Moreover, why a difference in interincisal distance of at least 5 mm is considered characteristic for an ADD is not substantiated in the RDC. It appears that there is no scientific basis for the 5-mm criterion; it is probably the result of the shared clinical experience from the authors of the RDC, which makes the 5-mm criterion a so-called “expert opinion.”

Therefore, the aim of this study was to test whether the 5-mm criterion of the RDC is characteristic for a click due to an ADD. This was done by simultaneously analyzing mandibular motion in the incisal and condylar regions at the time of clicking by means of a 6-degrees-of-freedom jaw movement recording device.

Materials and Methods

Participants

Thirty individuals, 25 women and 5 men aged from 17 to 58 years (mean \pm SD = 29.0 \pm 9.7), participated in the study. All gave informed consent to the procedures approved by the review board of the Netherlands Institute for Dental Sciences (IOT) and in accordance with the Helsinki Declaration. All participants had unilateral clicks due to an ADD. The presence of an ADD was clinically established as reciprocal clicking in the TMJ (click on both vertical opening and closing) that was eliminated on protrusive opening, and reproducible on 2 of 3 consecutive trials. Since the closing click is often hardly audible,

manual loading of the mandible was used to provoke the closing click.¹² The load was kept relatively small and symmetrical, so as to minimally influence the timing of the closing clicks and the movement paths of the mandible. Further, only participants were included for which the opto-electronic condylar movement recordings showed the movement characteristics of an ADD (Fig 1).^{13,14} All clinical examinations were done by 1 investigator. The opto-electronic movement recordings were made by a second investigator who was blind to the results of the clinical examination. Exclusion criteria comprised bilateral clicks, and opto-electronic condylar movement recordings that failed to show the movement characteristics of an ADD.

Recording Device

Mandibular movements were recorded by means of the OKAS-3D system, which is an opto-electronic device (custom-made) capable of accurately recording mandibular motion with 6 degrees of freedom at a sampling frequency of 300 Hz per coordinate. A detailed description of the recording device can be found elsewhere.¹⁵ With the use of the rigid body mathematics, the movements of any mandibular point relative to the skull can be reconstructed. Small microphones (condenser type) were placed over the palpated lateral pole of the clicking TMJ to record simultaneous joint sounds. A specialized software procedure graphically visualized the recorded movements of the incisal point or the condyle, together with the recorded joint sounds.¹⁶ Offline, recorded sounds were assigned as clicks due to an anteriorly displaced disc when they occurred at the time of a characteristic deflection in the condylar movements.

Reconstructed Points

The kinematic axis was suggested for the reconstruction of condylar movements by Kohno.¹⁷ This concept was adopted by Pröschel et al¹⁸ and slightly adapted and renamed to kinematic center by Yatabe et al.¹⁹ The kinematic center is the mathematical center of that part of the circular surface of the condyle-disc complex that stays in contact with the articular eminence during both opening and protrusion. As a consequence, movement traces of the kinematic center for these 2 tasks will coincide. This is described in detail by Naeije et al.²⁰ In the present study, the kinematic center was used for the reconstruction of the condylar movements. A specially developed soft-

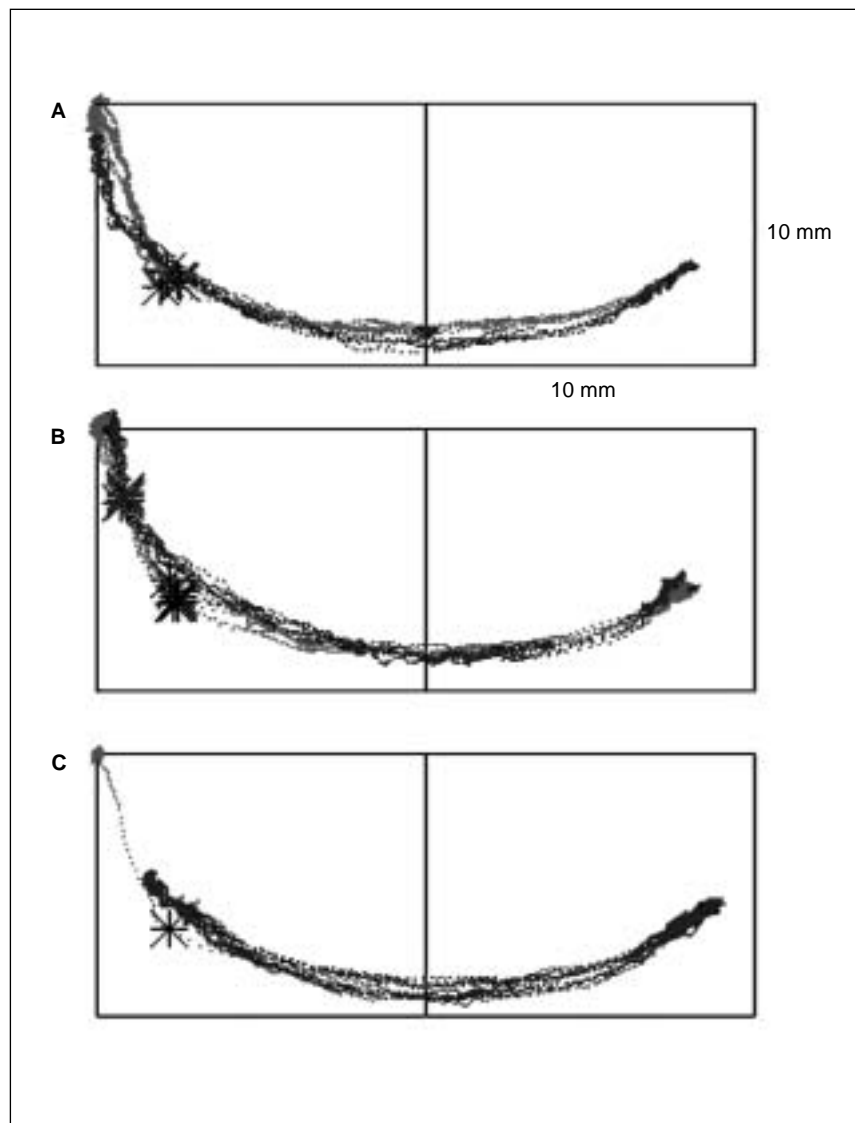


Fig 1 Superimposed sagittal kinematic movement traces of a joint with an opening and closing deflection at the time of clicking. The opening movement traces are red; the closing ones, blue. Clicks are indicated with an asterisk (*). During free opening and closing, no closing sounds could be detected (A). During free opening and loaded closing, closing sounds were also detected. Note that those parts of the opening and closing movement traces with a restored condyle-disc complex coincided (B). During protrusive opening and closing, a sound was detected only on the first opening movement (which started at the intercuspal position). Thereafter, all clicks were eliminated, while the condyle moved beyond the former position of the opening click (C).

ware procedure scanned the sagittal condylar plane for that point during which the opening and protrusive movements best coincided. The sagittal plane runs parallel to the medial plane of the participant's head and through the palpated lateral pole of the condyle.

The incisal point was used for the measurements of the amount of mouth opening. It is defined as the approximal contact point between the lower central incisors.

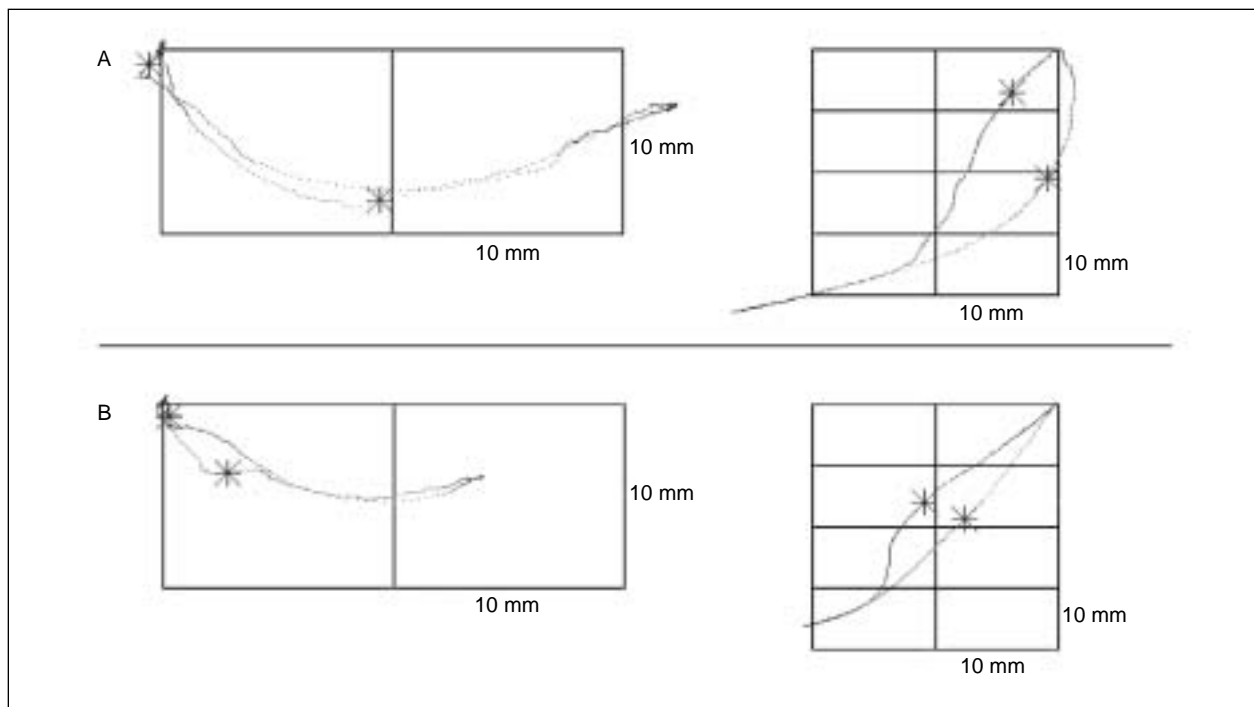


Fig 2 Examples of sagittal movement traces from 2 participants (A, B) with an ADD. The opening movement traces are red; the closing ones, blue. The traces show the simultaneous recording of the condylar distance (*left*) and the interincisal distance (*right*) at the time of the opening and the closing clicks. The opto-electronic movement recordings from both participants showed characteristic condylar movements of an ADD, but showed a different timing of the clicks for the incisal point. For participant "A," the difference in mouth opening between the opening and closing click is 14 mm, while for participant "B," the difference in mouth opening is only 3 mm, which is not in accordance with the 5-mm criterion.

Experimental Procedure

During the experiment, each participant was seated upright and could move his or her head freely within the range of the OKAS displays. In addition to obtaining recordings of opening and protrusion for the calculation of the kinematic center (see above), a 20-second recording was obtained with the participant performing unloaded opening and loaded closing movements. The closing movements were loaded with a manual, downward directed force (about 30 N) on the chin. This was done because the closing click is often hardly audible,¹¹ and vertical loading of the mandible during closing amplifies the closing click.¹²

Data Analysis

In order to analyze the positions of the opening and closing clicks, the following procedure was performed. The computer first calculated the position of the kinematic point (condylar position) and the incisal point (incisal position) within the sagittal plane. Thereafter, the distances between the

position of the kinematic or incisal point at maximum intercuspation and at the time of the click were computed both for the opening and closing click and were denoted as condylar or interincisal distance.

Statistical Analysis

A 1-way analysis of variance (ANOVA) was used to obtain an unbiased estimate for the within-subject standard deviation. In addition, the average interincisal distances and condylar positions within each participant were calculated. Their mean values were further analyzed with paired *t* tests and linear regressions. Probability levels of $P < .05$ were considered statistically significant.

Results

The analysis was limited to those mandibular movements during which both an opening click and a closing click were recorded. In that way, 1 to 11 movements could be analyzed, with an average of

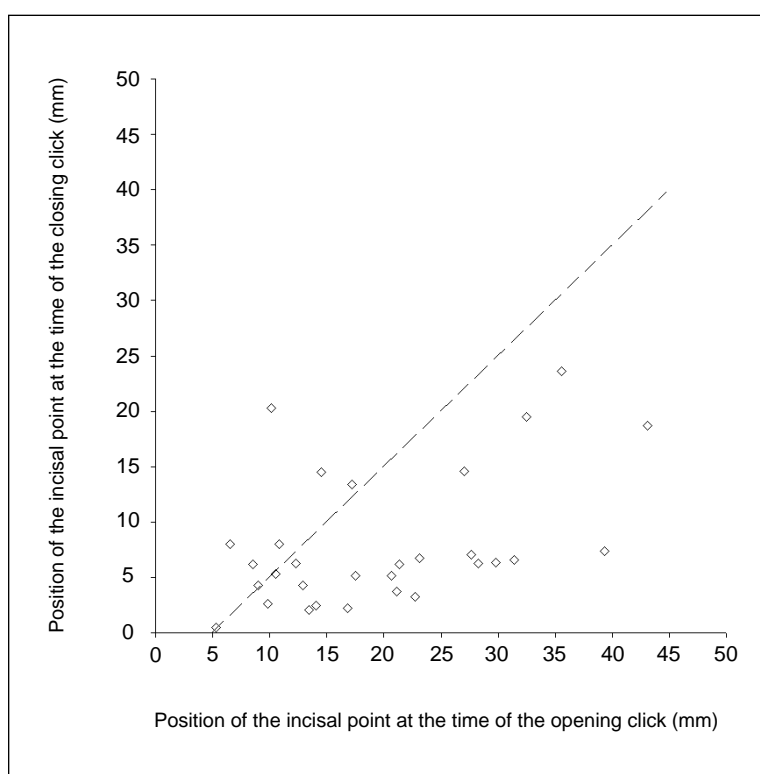


Fig 3 The relationship between the mean interincisal distances at the time of the opening and closing click for the 30 clicking joints. For the points below the oblique line, the interincisal distance on opening was at least 5 mm greater than on closing.

6.0 movements per participant. For the interincisal distance, the within-subject standard deviation was 1.9 mm for the opening click and 2.5 mm for the closing click. For the condylar distance, the respective values were 0.5 mm and 0.4 mm.

Figure 2 illustrates the opto-electronic movement recordings of 2 participants who both showed characteristic condylar movements of an ADD, but revealed a different timing of the clicks for the incisal point. In the present study, the average interincisal distance was 19.8 mm (SD 10.1 mm) for the opening clicks and 8.0 mm (SD 6.0 mm) for the closing clicks. The opening clicks occurred at a larger interincisal distance than the closing clicks ($t = 7.017$, $P = .000$). Figure 3 shows that for 22 participants (the 22 points below the oblique line), the interincisal distance on opening was at least 5 mm greater than on closing. For the other 8 participants, the difference in mouth opening between the opening and closing click was 5 mm or less. For 2 participants, the click while closing occurred with an even larger mouth opening than that while opening. No relationship was found between the interincisal distances at the time

of the opening and closing clicks ($R^2 = 0.21$, $P = .12$).

The average condylar distance was 7.3 mm (SD 4.5 mm) for the opening clicks and 1.5 mm (SD 1.1 mm) for the closing clicks. For all individuals, the opening clicks occurred at a condylar position farther away from intercuspular position than the closing clicks ($t = 7.244$, $P = .000$). Figure 4 shows that all closing clicks occurred just before occlusion. No relationship was found between the condylar distances at the time of the opening and closing click ($R^2 = 0.76$, $P = .14$).

Discussion

Although several methods are used for the recognition of an anterior disc displacement with reduction, no so-called "gold standard" is available yet. Magnetic resonance images (MRI) are often claimed to be highly diagnostic for the recognition of anterior disc displacement,²¹ but it has been demonstrated that up to 38% of MRIs of the TMJ in asymptomatic volunteers reveal a disc displace-

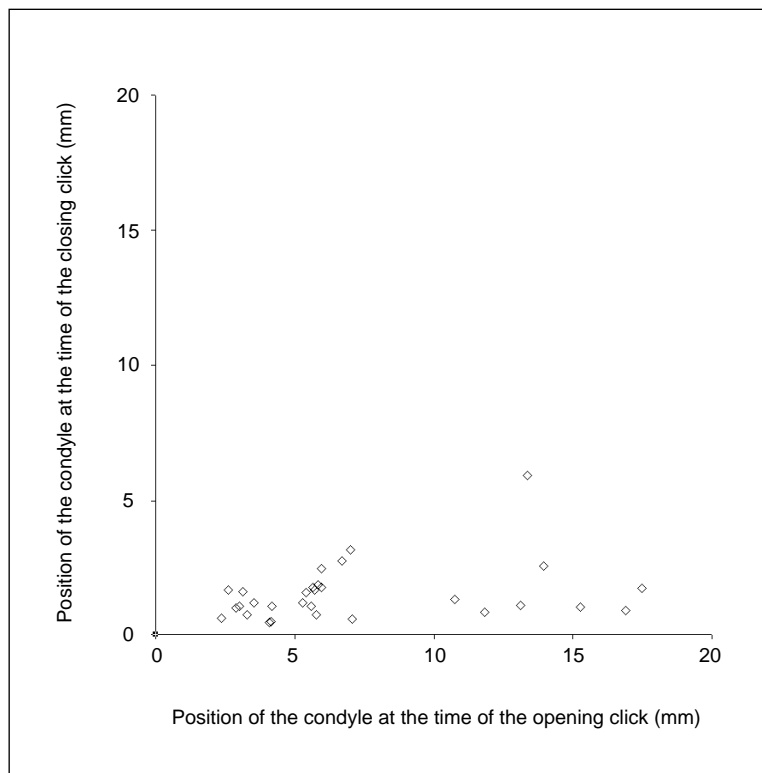


Fig 4 The relationship between the mean condylar distance at the time of the opening and closing click for the 30 clicking joints. Note the different scales for Figs 3 and 4.

ment.²² One of the possible causes for this problem is that MRIs give static information of the joint, ie, an image of the joint with the mouth closed is compared with an image with the mouth maximally opened. Six degrees of freedom optoelectronic movement traces, on the other hand, give dynamic information about the joint. With the aid of the latter method, it was shown that in clicking joints movement traces could be distinguished that are characteristic of an ADD.^{13,14} However, the condylar movement traces strongly depend upon the choice of the condylar reference point.²³ For the reconstruction of the condylar path, one can use, for instance, the palpated lateral pole, the terminal hinge axis, or the kinematic center.^{23,24} Naeije et al²⁰ and Pröschel et al¹⁸ recommend the use of the kinematic center as condylar reference, because it shows the least variation in the condylar movement traces when compared with other points.²⁰ Therefore, in the present study the combination of a clinical examination and the kinematic condylar movement traces were used for the recognition of an ADD.

In a clicking joint, the calculation to find the location of the kinematic center may be compromised because the condyle-disc relationship changes during mouth opening and closing. However, the condyle-disc relationship is restored on the part after the opening click on mouth opening and before the closing click on mouth closing. During free jaw opening and loaded jaw closing, the condyle-disc complex is in close contact with the articular eminence.¹² As a result, the opening and closing movement traces of the kinematic center should coincide for those parts of the opening and loaded closing movement traces in which the condyle-disc relationship was restored (Fig 1[B]). The fact that these parts of the movement traces coincided in the present study indicates that the calculation of the kinematic center was accurate.

In the present study, some interesting observations were made. First, the diagnostic criterion of the RDC for an ADD of a difference of at least 5 mm between the interincisal distances of the opening and closing clicks⁵ is not characteristic for all clicks due to an anterior disc displacement with

reduction. The 5-mm criterion was fulfilled in only 73% (22 of the 30 participants) of the recorded clicks. This, together with the fact that the within-subject standard deviations were relatively large (up to 2.5 mm), suggests that the 5-mm criterion may not be the best method for the diagnosis of an ADD. Of course, the main limitation of this study is the assumption that the RDC criteria, together with the characteristics of the condylar trajectories, validly prove an ADD. Therefore, the results of this study are valid only under the premise that this assumption is correct. The second part of the diagnostic criterion for an ADD,⁵ namely, clicking that is eliminated on protrusive opening, might be more accurate. Protrusive opening and closing will prevent the dislocation of the disc, since the condyle does not enter the final part of the fossa (Fig 1[C]). This test seems to be a more functionally and anatomically correct method to discriminate between subgroups of clicks than the 5-mm criterion.

Second, it was observed that all condylar distances at the time of the closing clicks lie just before occlusion (Fig 4). This implies that the closing clicks all occur in a restricted part of the closing movement path, while the opening clicks occur in a broad range of the opening movement. Apparently, in the presence of an ADD, the dislocation of the disc occurs just before the condyle reaches its terminal position, as also described by Farrar and McCarthy.²⁵ This observation is less apparent from the position of the incisal point at the time of the closing clicks, because the movements of the incisal point are the combined result of the translatory and rotatory movements of the mandible. When, for instance, the last phase of mandibular closing is dominated by the rotatory component,²⁶ the interincisal distance may still be relatively large, while the condyle is already situated in the fossa. The movements of the kinematic center, however, are insensitive to the rotatory component of movement, and thus give a proper indication of the position of the condyle at the time of the click. The fact that observations of clicking joints in the incisal region differ from those in the condylar region is corroborated by the study of Travers et al,²⁷ who concluded that in nonclicking joints, incisor opening does not provide reliable information about condylar translation; therefore, its use as a diagnostic indicator should be limited.

Although many theories have been proposed, the etiology of an ADD is still unknown.^{10,28} The

observation that the closing clicks always occur just before the condyle reaches its terminal position in the fossa points in the direction of an anatomical etiology. The articular surfaces of the TMJ are discongruent and in this respect, the articular disc is thought to have a space-correcting function.²⁹ The dislocation of the disc just before the condyle reaches its terminal position in the fossa may be indicative of a space problem within the joint, so that the condyle and the disc cannot be jointly accommodated in the fossa. As a compromise, the disc then gets anteriorly displaced.

In conclusion, the 5-mm criterion of the RDC is not characteristic for all clicks due to anterior disc displacement with reduction. Therefore, we recommend the use of the protrusive opening test to diagnose an ADD.

References

1. Greene CS, Marbach JJ. Epidemiologic studies of mandibular dysfunction: A critical review. *J Prosthet Dent* 1982;48(2):184-190.
2. Locker D, Slade G. Prevalence of symptoms associated with temporomandibular disorders in a Canadian population. *Community Dent Oral Epidemiol* 1988;16(5):310-313.
3. Glass EG, McGlynn FD, Glaros AG, Melton K, Romans K. Prevalence of temporomandibular disorder symptoms in a major metropolitan area. *Cranio* 1993;11(3):217-220.
4. Jensen R, Krogh Rasmussen B, Pedersen B, Lous I, Olesen J. Prevalence of oromandibular dysfunction in a general population. *J Orofac Pain* 1993;7(2):175-182.
5. Dworkin SF, LeResche L. Research diagnostic criteria for temporomandibular disorders: Review, criteria, examinations and specifications, critique. *J Craniomandib Disord* 1992;6(4):301-355.
6. The American Academy of Orofacial Pain. Okeson JP, ed. *Orofacial Pain: Guidelines for Assessment, Diagnosis, and Management*. Chicago: Quintessence, 1996.
7. Lundh H, Westesson PL, Kopp S. A three-year follow-up of patients with reciprocal temporomandibular joint clicking. *Oral Surg Oral Med Oral Pathol* 1987;63(5):530-533.
8. Farrar WB. Characteristics of the condylar path in internal derangements of the TMJ. *J Prosthet Dent* 1978;39(3):319-323.
9. Dolwick MF. Intra-articular disc displacement. Part I: Its questionable role in temporomandibular joint pathology. *J Oral Maxillofac Surg* 1995;53(9):1069-1072.
10. Könönen M, Waltimo A, Nyström M. Does clicking in adolescence lead to painful temporomandibular joint locking? *Lancet* 1996;347(9008):1080-1081.
11. The American Academy of Orofacial Pain. McNeill C, ed. *Temporomandibular Disorders: Guidelines for Classification, Assessment, and Management*. Chicago: Quintessence, 1993.

12. Huddleston Slater J, Visscher CM, Lobbezoo F, Naeije M. The intra-articular distance within the TMJ during free and loaded closing movements. *J Dent Res* 1999;78(12):1815–1820.
13. Huddleston Slater JR, Naeije M. Classification of kinematic condylar movement traces from clicking TM joints [abstract 3172]. *J Dent Res* 1998 (special issue B); 77:1028.
14. Mauderli AP, Lundeen HC, Loughner B. Condylar movement recordings for analyzing TMJ derangements. *J Craniomandib Disord* 1988;2(3):119–127.
15. Naeije M, Van der Weijden JJ, Megens CC. OKAS-3D: An opto-electronic jaw movement recording system with six degrees of freedom. *Med Biol Eng Comput* 1995; 33(5):683–688.
16. Yatabe M, Zwijnenburg A, Megens CC, Naeije M. Movements of the mandibular condyle kinematic center during jaw opening and closing. *J Dent Res* 1997;76(2):714–719.
17. Kohno S. A study on condylar movements with reference to the mandibular movement in the sagittal plane: Analysis of sagittal axis with the multiple electronic flush apparatus. *J Jpn Prosthet Soc* 1968;12:350–380.
18. Pröschel P, Feng H, Ohkawa S, Ott R, Hofman M. Untersuchung zur Interpretation des Bewegungsverhaltens kondylärer Punkte. *Dtsch Zahnärztl Z* 1993;48:323–326.
19. Yatabe M, Zwijnenburg A, Megens CC, Naeije M. The kinematic center: A reference for condylar movements. *J Dent Res* 1995;74(10):1644–1648.
20. Naeije M, Huddleston Slater JJR, Lobbezoo F. Variation in movement traces of the kinematic center of the temporomandibular joint. *J Orofac Pain* 1999;13(2):121–127.
21. Gibbs SJ, Simmons HC III. A protocol for magnetic resonance imaging of the temporomandibular joints. *Cranio* 1998;16(4):236–241.
22. Kircos LT, Ortendahl DA, Mark AS, Arakawa M. Magnetic resonance imaging of the TMJ disc in asymptomatic volunteers. *J Oral Maxillofac Surg* 1987;45(10):852–854.
23. Zwijnenburg A, Megens CCEJ, Naeije M. Influence of choice of reference points on the condylar movement paths during mandibular movements. *J Oral Rehabil* 1996;23(12):832–837.
24. Catiç A, Naeije M. Location of the hinge axis and the kinematic center in asymptomatic and clicking temporomandibular joints. *J Oral Rehabil* 1999;26(8):661–665.
25. Farrar WB, McCarty WL. *A Clinical Outline of Temporomandibular Joint Diagnosis and Treatment*, 7th edition. Montgomery: Normandie, 1982.
26. Merlini L, Palla S. The relationship between condylar rotation and anterior translation in healthy and clicking temporomandibular joints. *Schweiz Monatsschr Zahnmed.* 1988;98(11):1191–1199.
27. Travers KH, Buschang PH, Hayasaki H, Trockmorton GS. Associations between incisor and mandibular condylar movements during maximum mouth opening in humans. *Arch Oral Biol* 2000;45(4):267–275.
28. Tenenbaum HC, Freeman BV, Psutka DJ, Baker GI. Temporomandibular disorders: Disc displacements. *J Orofac Pain* 1999;13(4):285–290.
29. Ten Cate R. Gross and micro anatomy. In: Zarb GA, Carlsson GE, Sessle BJ, Mohl N (eds). *Temporomandibular Joint and Masticatory Muscle Disorders*. Copenhagen: Munksgaard, 1994:48–66.