

Ectopic Presence of Tooth Within the Mandibular Condyle

Yun-Heon Song, DDS, PhD

Private practice
TMJ & Orofacial Pain Center
Ahrim Dental Hospital
Gangnam-gu, Seoul, Korea

Il-Ho Tae, DDS, PhD

Private practice
TMJ & Orofacial Pain Center
Ahrim Dental Hospital
Gangnam-gu, Seoul, Korea

Young Han Kim, DDS, PhD

Private practice
TMJ & Orofacial Pain Center
Ahrim Dental Hospital
Gangnam-gu, Seoul, Korea

Youn Joong Kim, DDS, PhD

Private practice
TMJ & Orofacial Pain Center
Ahrim Dental Hospital
Gangnam-gu, Seoul, Korea

Correspondence to:

Dr Youn Joong Kim
TMJ & Orofacial Pain Center
Ahrim Dental Hospital
158-12 Samsung-dong
Seoyoung Bldg 15-16 Fl
Gangnam-gu
Seoul 135-090, Korea
Fax: 82-2-515-9675
Email: tmjdoctor@hanmail.net

©2014 by Quintessence Publishing Co Inc.

This article describes the case of a 41-year-old woman who presented with the complaint of crepitation sound and mild pain in the left temporomandibular joint area. Panoramic radiographs taken to rule out degenerative or arthritic changes in the joints demonstrated a radiopaque mass within the left condyle. Cone beam computed tomography scans revealed an ectopic tooth located centrally within the left condyle. Thus, while considered rare, the mandibular condyle can be a possible location of an ectopic tooth. *J Oral Facial Pain Headache* 2014;28:360–362. doi: 10.11607/ofph.960

Panoramic radiographs are often employed as part of routine dental examinations. Panoramic and temporomandibular joint (TMJ) radiographs may also be utilized for the evaluation of temporomandibular disorders (TMD). During these radiographic evaluations, clinicians may encounter pathologic findings not relevant to the TMD or to the primary complaint. That was the case for the patient described in this article, who had an ectopic tooth located within the left mandibular condyle, but came to Ahrim Dental Hospital, Seoul, Korea, because of TMJ sounds and discomfort.

Case Report

A 41-year-old woman presented with a complaint of mild pain that had persisted for the past 2 weeks in the left TMJ area during chewing and wide jaw opening. At the time of the visit, the pain was improving and was no longer a significant complaint. In addition, she reported a crepitation sound in the left TMJ.

The patient did not have a history of serious illnesses or other diseases relevant to her complaints. She reported a history of habits including nocturnal tooth clenching, unilateral chewing on the left, and sleeping on her side.

The clinical examination revealed a nonpainful maximum jaw opening of 43 mm interincisal distance. The TMJs and masticatory muscles were not tender to palpation, but TMJ palpation revealed a crepitation in the left TMJ during mandibular movements. The oral examination disclosed an Angle Class II, division 2 malocclusion. All teeth were present with the exception of the mandibular right third molar, the mandibular left second and third molars, and the maxillary third molars. The maxillary left second molar was supraerupted into the opposing edentulous space. Severe attrition of the maxillary and mandibular anterior teeth was apparent. A soft tissue examination disclosed bilateral ridging of the buccal mucosa and a crenated tongue.

The panoramic radiograph taken to rule out degenerative or arthritic joint changes demonstrated flattening of both condyles and a radiopaque mass within the left condyle (Fig 1). Bilateral cone beam computed tomography (CBCT) scans (Implagraphy, Vatech Co), taken to better depict the radiopaque mass, showed that this was due to an ectopic tooth located centrally within the left condyle, with the crown pointing upwards, and surrounded by a radiolucent area (Fig 2). On the

Fig 1 Panoramic radiograph. A radiopaque area is visible just below the left condyle.

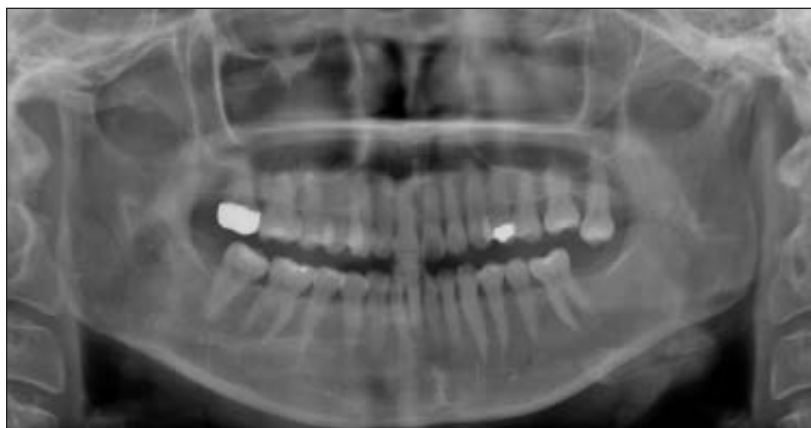


Fig 2 Coronal and sagittal views of the left condyle taken by cone beam computed tomography clearly show the tooth.

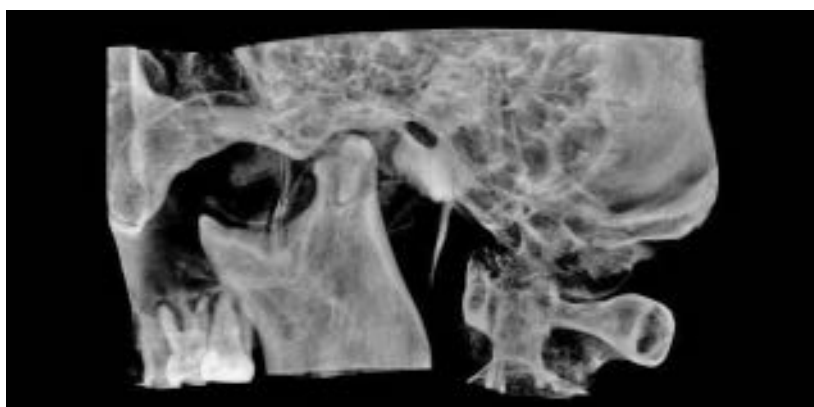
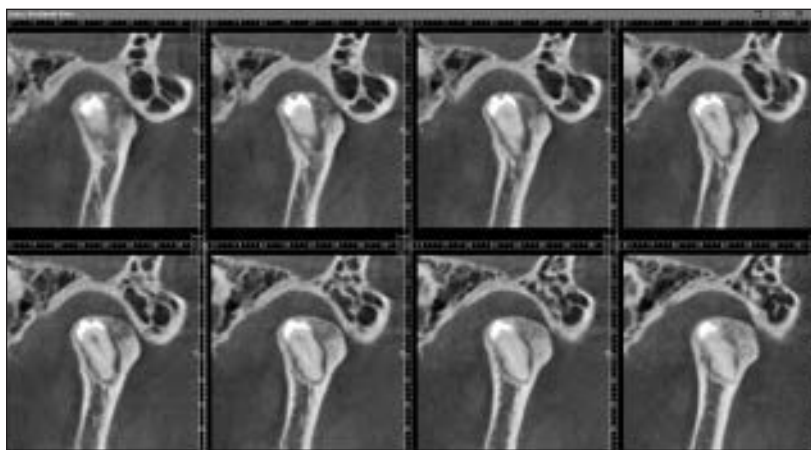

Fig 3 Cone beam computed tomography image: Radiopaque mass resembling a pre-molar tooth is visible in the mandibular condyle (InVivoDental, Anatomage).

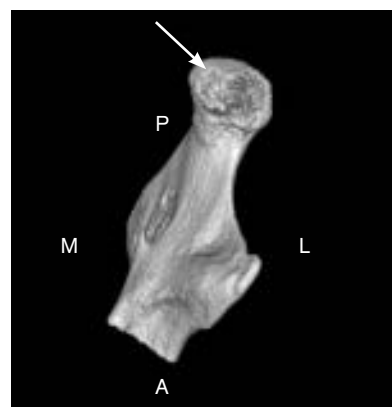


Fig 4 Cone beam computed tomography image: Arrow shows that the cranial cortical surface of the condyle is not perforated but has a rough appearance. A = anterior; P = posterior; L = lateral; M = medial.

three-dimensional view, the superior cortical surface of the left condyle viewed from above the temporal fossa removed by the software did not exhibit any discontinuity but had a rough appearance (Figs 3 and 4).

Because the patient complained of pain in the TMJ caused by inflammation, she was advised to follow a physical treatment protocol and use nonsteroidal

anti-inflammatory agents for 1 week to facilitate reduction of the inflammation even though the pain was already subsiding. The patient was advised not to pursue surgical treatment. However, periodic radiographic examinations were recommended to determine if there was any movement of the toothlike structure.

Discussion

The ectopic presence of a tooth in the mandible has been reported by several authors, with the mandibular third molar being the most often ectopically impacted tooth. Among the 13 cases of third molar impaction in the ramus region reported between 1960 and 1978, only 6 were found in the condylar region or the coronoid process, and all of these involved dentigerous cysts.¹ An impacted third molar has been described at different levels of the mandibular ramus,² coronoid process,^{3,4} as well as in the condylar⁵⁻⁷ and subcondylar^{1,8} regions.⁹ The presence of an ectopic supernumerary tooth within the mandibular condyle has never been reported, to the authors' knowledge. It cannot be ruled out that the ectopic tooth described in this case report was a supernumerary tooth. However, in order to decide whether the tooth was indeed supernumerary, it would have been necessary to have previous panoramic radiographs and a thorough detailed history of previous tooth extractions.

It is also impossible to know whether the ectopic tooth was formed in the condyle or migrated there. Tooth migration into the coronoid process has been reported¹⁰ in a 12-year-old child, in whom an inclined first premolar moved approximately 5 cm during the following 10 years to become located below the coronoid process when the patient was 23 years of age. Okada and coauthors described two cases of ectopic eruption of premolars in the coronoid process and condylar neck, respectively; the nonerupted premolars translated horizontally or distally in the direction of the tooth crown, which maintained the lead during migration.¹¹

The ectopic tooth in the present case was surrounded by a radiolucent area, but it is not known whether this was due to arthritic changes, eruptive forces, or other factors.

An irregular surface, likely the cause of the crepitation sound reported by the patient, was seen when the condyle was viewed from above in a CBCT image that had the temporal fossa removed by the software.

In conclusion, while considered rare, the mandibular condyle can be a possible location of an ectopic tooth.

References

1. Burton DJ, Scheffer RB. Serratia infection in a patient with bilateral subcondylar impacted third molars and associated dentigerous cysts: Report of case. *J Oral Surg* 1980;38:135-138.
2. Markowitz NR, Wolford DG, Harrington WS, Monaco F. Bilateral vertical impacted third molars of the midramus. *Oral Surg Oral Med Oral Pathol Oral Radiol Endod* 1979;47:107.
3. Muller EJ. Tooth in coronoid process. *Oral Surg Oral Med Oral Pathol Oral Radiol Endod* 1983;55:327.
4. Gunther G. Tooth in coronoid process. *Oral Surg Oral Med Oral Pathol Oral Radiol Endod* 1976;42:539.
5. Wassouf A, Eyrih G, Lebeda R, Grätz KW. Surgical removal of a dislocated lower third molar from the condyle region: Case report. *Schweiz Monatsschr Zahnmed* 2003;113:416-420.
6. Medici A, Raho MT, Anghinoni M. Ectopic third molar in the condylar process: Case report. *Acta Biomed Ateneo Parmense* 2001;72:115-118.
7. Salmerón JI, del Amo A, Plasencia J, Pujol R, Vila CN. Ectopic third molar in condylar region. *Int J Oral Maxillofac Surg* 2008;37:398-400.
8. Bux P, Lisco V. Ectopic third molar associated with a dentigerous cyst in the subcondylar region: Report of case. *J Oral Maxillofac Surg* 1994;52:630-632.
9. Wang CC, Kok SH, Hou LT, et al. Ectopic mandibular third molar in the ramus region: Report of a case and literature review. *Oral Surg Oral Med Oral Pathol Oral Radiol Endod* 2008;105:155-161.
10. Sutton P. Migrating nonerupted mandibular premolars: A case of migration into the coronoid process. *Oral Surg Oral Med Oral Pathol* 1968;25:87-98.
11. Okada H, Miyake S, Toyama K, Yamamoto H. Intraosseous tooth migration of impacted mandibular premolar: Computed tomography observation of 2 cases of migration into the mandibular neck and the coronoid process. *J Oral Maxillofac Surg* 2002;60:686-689.