

Bony Deviations Revealed by Cone Beam Computed Tomography of the Temporomandibular Joint in Subjects Without Ongoing Pain

Merete Bakke, DDS, PhD, Dr Odont

Associate Professor
Section of Oral Medicine (Clinical Oral Physiology)
Department of Odontology
Faculty of Health and Medical Sciences
University of Copenhagen
Copenhagen, Denmark

Arne Petersson, DDS, Odont Dr

Professor Emeritus
Section of Radiology
Department of Odontology
Faculty of Health and Medical Sciences
University of Copenhagen
Copenhagen, Denmark

Mie Wiese, DDS, PhD

Senior Clinical Instructor
Section of Radiology
Department of Odontology
Faculty of Health Medical Sciences
University of Copenhagen
Copenhagen, Denmark

Palle Svanholt, DDS

Consultant Orthodontist
Obstructive Sleep Apnoea Clinic
Section of Orthodontics
Department of Odontology
Faculty of Health and Medical Sciences
University of Copenhagen
Copenhagen, Denmark

Liselotte Sonnesen, DDS, PhD, Dr Odont

Associate Professor
Section of Orthodontics
Department of Odontology
Faculty of Health and Medical Sciences
University of Copenhagen
Copenhagen, Denmark

Correspondence to:

Dr Merete Bakke
Section of Oral Medicine
(Clinical Oral Physiology)
Department of Odontology
Faculty of Health and Medical Sciences
University of Copenhagen
20 Nørre Allé
DK-2200, Copenhagen N
Denmark
Fax: +45-35-326-722
Email: mbak@sund.ku.dk

©2014 by Quintessence Publishing Co Inc.

Aims: To assess the prevalence of temporomandibular joint (TMJ) bony changes in cone beam computed tomography (CBCT) images of adult subjects without ongoing orofacial pain or complaints from the TMJ. **Methods:** The study included 84 TMJs from 28 men and 14 women (mean age [\pm SD]: 51 ± 11 years) without orofacial pain or TMJ complaints who were participants in a study of patients with obstructive sleep apnea. They were examined before any treatment with the Research Diagnostic Criteria for Temporomandibular Disorders and with CBCT (NewTom VGi; 15×15 cm, exposure time 18 seconds, axial thickness 0.3 mm). Osseous TMJ deviations were assessed blindly and classified. **Results:** Degenerative changes were noted in the CBCT images of 33 (39.3%) of the TMJs, of which 21 were classified as osteoarthritic alterations and 12 as indeterminate changes of osteoarthritis. Two TMJs were clinically classified as osteoarthrosis and 6 as disc displacement with reduction. The CBCT images of the 2 TMJs with a clinical diagnosis of osteoarthrosis showed also bony changes, but the CBCT images also revealed osteoarthritic bony changes in the 18 TMJs without any clinical diagnosis. **Conclusion:** CBCT images of asymptomatic adult TMJs commonly show degenerative bony alterations. Accordingly, such radiographic findings should be used with care and only as a supplement to clinical assessment. *J Oral Facial Pain Headache 2014;28:331-337. doi: 10.11607/ofph.1255*

Key words: cone beam computed tomography, imaging, Nordic Orofacial Test-Screening, osteoarthritis, osteoarthrosis, RDC/TMD, temporomandibular joint

Epidemiologic studies have shown that temporomandibular disorders (TMD) are present in about 10% of the adult population, and that about 3% have disorders of the temporomandibular joint (TMJ) that need treatment.^{1,2} Disc displacements with clicking or reduced jaw mobility are the most frequent TMD, while painful osteoarthritis is less frequent.

Ahmad et al have discussed the differences regarding the diagnostic terms of osteoarthritis and osteoarthrosis.³ In the Research Diagnostic Criteria for TMD (RDC/TMD), the definition of osteoarthrosis involves the absence of pain and that of osteoarthritis the presence of pain, but the radiologic findings are similar.⁴ Ahmad et al defined subcortical cysts, surface erosion, osteophytes, or generalized sclerosis as the diagnostic criteria for the radiographic diagnosis of osteoarthritis (Table 1), and they proposed to use the diagnostic term of osteoarthritis in the case of radiographic bony changes in the absence of clinical information.³ The same authors defined flattening of the articular surfaces and localized subcortical sclerosis as radiographic bony changes "indeterminate for osteoarthritis."

The bony changes are most commonly seen on the condyle but may also involve the mandibular fossa or tubercular eminence, and there is an increased likelihood of degenerative findings in radiographs of TMJs with coarse crepitus.^{5,6} The radiographic manifestations of osteoarthritis and inflammatory arthritis are similar, but the degree of joint destruction is typically more pronounced in inflammatory arthritis.

Cone beam computed tomography (CBCT) is becoming the modality of choice for the evaluation of the osseous components of the TMJ. Computed tomography (CT) has been proposed to be used in

Table 1 Assessment of the Osseous Components of the TMJ from Radiographs and Comprehensive Radiographic Diagnostic Criteria*

No osteoarthritis

Normal relative size of the condylar head; and
No subcortical sclerosis or articular surface flattening; and
No deformation due to subcortical cyst, surface erosion,
osteophyte, or generalized sclerosis

Indeterminate osteoarthritis

Normal relative size of the condylar head; and
Subcortical sclerosis with/without articular surface flattening; or
Articular surface flattening with/without subcortical sclerosis; and
No deformation due to subcortical cyst, surface erosion,
osteophyte, or generalized sclerosis

Osteoarthritis

Deformation due to subcortical cyst, surface erosion,
osteophyte, or generalized sclerosis

*After Ahmad et al.³

the RDC/TMD protocol,³ but the recently developed Diagnostic Criteria for TMD (DC/TMD) also have proposed that CBCT can be used instead of CT when indicated.⁷ CBCT allows the visualization of the TMJ in all three planes with high resolution, minimal distortion, and great accuracy for detecting condylar cortical erosions.⁸ The goals of TMJ imaging by CBCT are to evaluate the integrity of the bony structures when disorders are suspected, typically in patients with TMJ pain and capsular tenderness, and to confirm the extent and progression of any bony changes.⁹ Imaging should therefore only be performed after a thorough history and clinical examination which indicate that more information is needed, or when specific documentation is relevant.

The RDC/TMD do not require imaging of the TMJ for joint diagnosis.⁴ The RDC/TMD Axis I diagnostic system has been employed internationally for many years. The diagnosis primarily has been based on clinical signs and symptoms.¹⁰ Only when accessible, imaging was recommended to help differentiate between the three disc displacement diagnoses in Group II and the diagnoses of arthralgia, osteoarthritis, and osteoarthritis in Group III. However, no criteria for the interpretation of the images were specified, and it is only recently that radiologic criteria for the diagnosis of osteoarthritis by CT (Table 1) and disc displacement by magnetic resonance imaging have been developed.³ In addition, the radiologic findings of the TMJ do not always support the clinical RDC/TMD diagnosis.¹¹

Like other radiographic techniques, CBCT lacks the ability to discriminate asymptomatic from symptomatic joints.¹¹ Accordingly, poor correlations have been shown between pain and other clinical signs and symptoms of TMJ osteoarthritis and condylar bony changes in CBCT images.¹² Indeed, in 11% of the patients with obstructive sleep apnea (OSA) and in 18% of control subjects, CBCT images showed

incidental radiographic signs of degenerative joint disease or osteoarthritis of the TMJs.¹³ Also the progression and severity of osseous TMJ changes may increase with age and female gender.^{14,15} Thus, if bony changes are not primarily associated with TMD, it is important to know the prevalence of such alterations in a non-TMD population. Therefore, the aim of the present study was to assess the prevalence of TMJ bony changes in CBCT images of adult subjects without ongoing orofacial pain or TMJ complaints.

Materials and Methods

Participants

The study included data from 42 consecutive subjects (28 men and 14 women with a median age of 53 years; Table 2) referred from ear, nose, and throat (ENT) specialists over a 9-month period for treatment with mandibular advancement oral appliances as part of a study on adult OSA at the Obstructive Sleep Apnea Clinic, Department of Odontology, University of Copenhagen. The investigation followed the guidelines of the Helsinki Declaration and was approved by the National Committee on Biomedical Research Ethics (Protocol H-3-2011.086). Informed consent was obtained from each subject.

None of the subjects included in the study had present pain or TMJ complaints. They were also without systemic inflammatory joint diseases or neuromuscular disorders, but more than half of them were treated with drugs for various medical conditions. As a mandibular advancement oral appliance for snoring and OSA may produce TMJ discomfort or pain, ongoing TMJ pain, TMJ complaints, and need of TMD treatment were exclusion criteria.¹⁶ Thus, the subjects were examined with respect to orofacial and TMJ function before inclusion in the study. The examination consisted of clinical and radiographic components. The clinical examination and CBCT radiographic evaluation were performed by separate investigators blinded to the findings of the other examination.

Clinical Examination

The Nordic Orofacial Test–Screening (NOT–S) was used to perform a comprehensive screening of orofacial dysfunction.¹⁷ It consisted of a structured interview and a clinical examination. The interview reflected six domains (sensory function, breathing, habits, chewing and swallowing, drooling, dryness of the mouth), and the examination included six domains (the face at rest, nose breathing, facial expression, masticatory muscle and jaw function, oral motor function, speech). One or more “yes” responses for impairment in one of the 12 domains scored 1 point, and the maximum score was 12 points.

Potential TMJ conditions were classified according to the algorithms of the RDC/TMD Axis I (International RDC/TMD Consortium Network).^{4,9} TMJ tenderness and TMJ sounds were recorded according to the RDC/TMD protocol by two of the authors (MB and LS) who were calibrated from other studies (eg, Sonnesen et al¹⁸).

Radiologic Examination

The CBCT images were taken with the teeth in occlusion and in the standardized head posture as described by Siersbæk-Nielsen and Solow.¹⁹ The CBCT unit was a NewTom VGi (Quantitative Radiology). The exposure settings were as follows: standard scan mode with an imaging volume of 15 cm × 15 cm, exposure time of 18 seconds, and axial thickness of 0.3 mm. Reconstructions of the TMJs were made from the volumetric data by using the NewTom NNT software. Individual cross-sections were produced with sagittal sections perpendicular and coronal images parallel to the mediolateral long axis of the condyle. The section thickness was 2 to 3 mm for sagittal sections and 1 to 2 mm for coronal sections. The multiplanar reformatting function with a section thickness of 0.3 mm was used in cases of uncertain findings. The images were saved in the program.

Two of the authors (AP and MW) analyzed the images individually. The observers were calibrated from another study using cross-sectional tomography.⁶ The registrations of the two observers were compared, and in case of discrepancy the final diagnosis was reached by consensus and dubious findings were not reported. The observers were blinded to the clinical findings. According to Ahmad et al,³ hard tissue changes such as a deviation in the relative size of the condyle, articular surface flattening, localized subcortical sclerosis, subcortical cyst, surface erosion, osteophyte, and generalized sclerosis were assessed for condyle, fossa, and eminence, and the following diagnoses were allowed: no osteoarthritis/osteoarthritis, indeterminate changes for osteoarthritis, and osteoarthritis (Table 1).

Statistical Analyses

The data were first analyzed with descriptive statistics (mean, median, standard deviation, and range). The association between the RDC/TMD diagnoses of osteoarthritis and the presence of indeterminate osteoarthritic/osteoarthritic changes in the CBCT images were analyzed with chi-square tests. In addition, the association between age and bony changes and the RDC/TMD diagnoses of osteoarthritis, respectively, was analyzed with Spearman rank order correlation (r_s). Statistical significance was accepted at $P < .05$, and all statistical analyses were calculated using Statistica, version 5.0 (StatSoft).

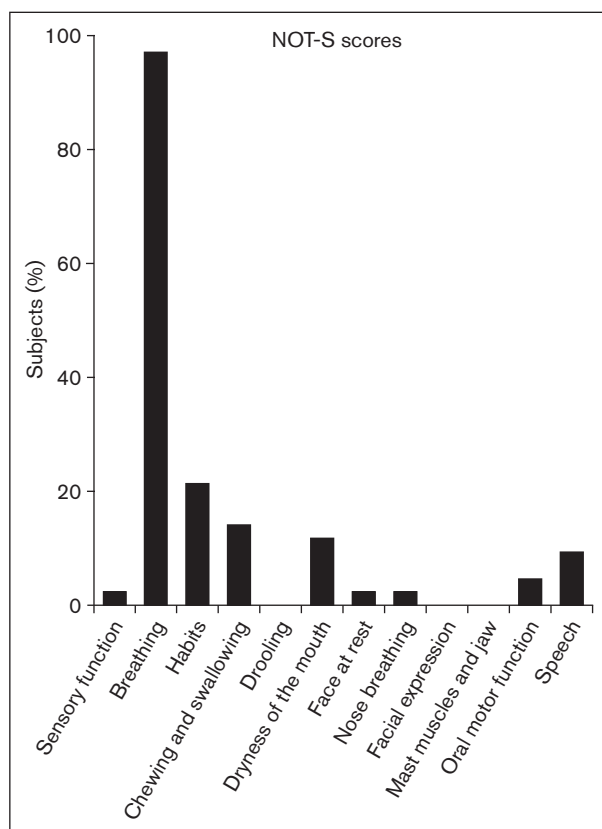


Fig 1 Orofacial dysfunction profile for the 42 participants with OSA included in the study. Percentage of subjects in each domain of the NOT-S. Almost 98% reported dysfunction in the breathing domain; otherwise, the findings were within the reference values for healthy subjects. Mast = masticatory.

Results

Nearly all subjects reported dysfunction in the breathing domain of the NOT-S screening corresponding to their OSA condition (Fig 1); otherwise, the total scores of the NOT-S screening (Table 2) were within the normal reference values.¹⁷ The maximal jaw-opening capacity and the number of teeth (Table 2) also were within reference values.²⁰

The clinical examination revealed that 8 subjects (19.0%) had a TMJ diagnosis according to the RDC/TMD: 2 joints (2.4%) in 2 subjects had osteoarthritis (Group IIIc), and 6 joints (7.1%) in 6 subjects had disc displacement with reduction (Group IIa) (Table 3).

Radiologic bony changes were found in 33 (39.3%) joints (Table 4). The changes were not significantly associated with age (osteoarthritic alterations, $r_s = 0.13$, $P = .24$; all bony alterations, $r_s = 0.01$, $P = .89$). Flattening was present in 31.0% of the TMJs, and erosions and osteophytes in 14.3% and 16.7%, respectively (Table 4). The radiologic findings of the CBCT images according to Ahmad et al³ (Table 1) led

Table 2 Description of 42 Subjects With OSA and Without Ongoing Orofacial Pain or Complaints from the TMJ

| | Age (y) | NOT-S* (0–12) | Maximal jaw opening capacity (mm) | Teeth present (n) |
|------------------------------|---------|---------------|-----------------------------------|-------------------|
| All subjects (n = 42) | | | | |
| Mean ± SD | 51 ± 11 | 1.7 ± 0.8 | 54 ± 5 | 28 ± 2 |
| Median | 53 | 1 | 55 | 28 |
| Range | 26–73 | 0–4 | 42–60 | 21–32 |
| Males (n = 28) | | | | |
| Mean ± SD | 50 ± 11 | 1.7 ± 0.9 | 53 ± 5 | 28 ± 3 |
| Median | 51 | 2 | 55 | 28 |
| Range | 27–71 | 1–4 | 42–60 | 21–32 |
| Females (n = 14) | | | | |
| Mean ± SD | 54 ± 12 | 1.4 ± 0.8 | 53 ± 3 | 28 ± 2 |
| Median | 56 | 1 | 54 | 28 |
| Range | 26–73 | 0–3 | 47–58 | 24–31 |

*Nordic Orofacial Test–Screening reference (normal) values range from 0 to 2.¹⁷

Table 3 No. (%) of Clinical Findings and Diagnoses of the TMJs in 42 Subjects Without Ongoing Orofacial Pain or TMJ Complaints

| | TMJ tenderness on palpation | TMJ sounds | | RDC/TMD* clinical diagnoses | |
|----------------------|-----------------------------|------------|-----------|-----------------------------|------------|
| | | Clicking | Crepitus | Group IIa | Group IIIc |
| All TMJs (n = 84) | 13 (15.5%) | 11 (11.9%) | 6 (7.1%) | 6 (7.1%) | 2 (2.4%) |
| Male TMJs (n = 56) | 10 (17.9%) | 7 (12.5%) | 2 (3.6%) | 4 (7.1%) | 1 (1.8%) |
| Female TMJs (n = 28) | 3 (10.7%) | 4 (14.3%) | 4 (14.3%) | 2 (7.1%) | 1 (3.6%) |

*International RDC/TMD Consortium Network¹⁹: IIa, disc displacement with reduction (click on both opening and closing or on either opening or closing, click eliminated during protrusive or provoked during jaw contralateral movements); IIIc, osteoarthritis (neither palpation pain nor pain report, coarse crepitus in TMJ during any movement).

Table 4 No. (%) of Types of Radiographic Bony Alterations of the TMJs* in 42 Subjects Without Ongoing Orofacial Pain or TMJ Complaints

| | Sclerosis | | | Subcortical cyst | Erosion | Osteophyte | Total assessment of osseous CBCT deviations [†] | |
|----------------------|------------|-----------|----------|------------------|------------|------------|--|----------------|
| | Flattening | Localized | General | | | | Indeterminate of osteoarthritis | Osteoarthritis |
| All TMJs (n = 84) | 26 (31.0%) | 4 (4.8%) | 0 (0.0%) | 2 (2.4%) | 12 (14.3%) | 14 (16.7%) | 12 (14.3%) | 21 (25.0%) |
| Male TMJs (n = 56) | 19 (33.9%) | 0 (0.0%) | 0 (0.0%) | 0 (0.0%) | 5 (8.9%) | 9 (16.1%) | 10 (17.9%) | 11 (19.6%) |
| Female TMJs (n = 28) | 7 (25.0%) | 4 (14.3%) | 0 (0.0%) | 2 (7.1%) | 7 (25.0%) | 5 (17.9%) | 2 (7.1%) | 10 (35.7%) |

*Findings of the mandibular condyle, fossa, and articular tubercle with CBCT (from no to several types of alterations in each joint).

[†]Comprehensive radiographic diagnostic criteria after Ahmad et al⁹ (see Table 1).

in 21 (25.0%) of the TMJs to the diagnosis of osteoarthritis of the TMJs (in 14 subjects), and in 12 (14.3%) to the diagnosis of indeterminate osteoarthritis (Table 4); 22 of the 42 subjects (52.4%) were without any osteoarthritic or indeterminate osteoarthritic alterations.

The number of TMJs showing osteoarthritic changes in the CBCT (21 TMJs, Table 4) was significantly larger than the number with osteoarthritis

(2 TMJs), based on RDC/TMD diagnoses ($P = .0001$). The two TMJs with the clinical diagnosis of osteoarthritis also showed osteoarthritic radiographic changes (osteoarthritic deviations, $r_s = 0.26$, $P = .02$; Table 5), but 18 TMJs with no RDC/TMD diagnosis had osteoarthritic changes in the CBCT images, similar to those seen in the radiographs of the two TMJs with osteoarthritis (see examples in Figs 2 and 3).

Table 5 Relationship Between Clinical Diagnoses (RDC/TMD) and Radiographic Findings (CBCT) in TMJs of 42 Subjects Without Ongoing Orofacial Pain or TMJ Complaints

| RDC/TMD | Assessment of osseous radiographic alterations* | | |
|--|---|--|-----------------------------|
| | None (51 TMJs) | Indeterminate of osteoarthritis (12 TMJs) | Osteoarthritis (21 TMJs) |
| No TMJ diagnosis (76 TMJs) | 49 | 9 | 18 |
| Disc displacement with reduction, Group IIa (6 TMJs) | 2 | 3 | 1 |
| Osteoarthritis, Group IIIc (2 TMJs) | 0 | 0 | 2 |

*After Ahmad et al³ (see Table 1).

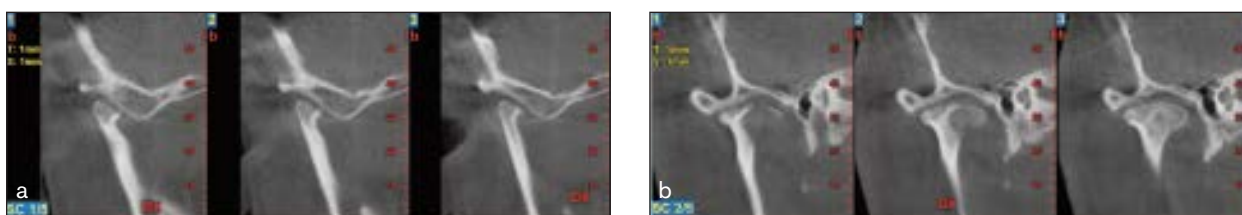

Fig 2 CBCT images of a TMJ of a patient without a RDC/TMD diagnosis but with bony osteoarthritic changes (erosions and osteophyte). (a) Sagittal. (b) Coronal.

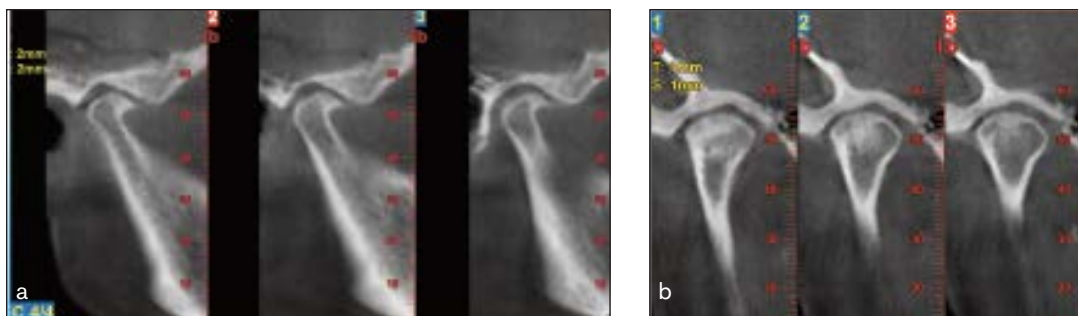

Fig 3 CBCT images of a TMJ of a patient with a RDC/TMD diagnosis of osteoarthritis and with osteoarthritic changes (erosions and osteophyte). (a) Sagittal. (b) Coronal.

Discussion

As part of an OSA study, CBCT images from subjects without ongoing pain or other TMJ complaints were analyzed for radiographic bony changes. More men than women were included in the study, consistent with the sex distribution of patients with adult OSA.²¹ Except from the snoring subscale, the NOT-S scores of these OSA patients were within the reference values of healthy subjects.

The clinical examination led to only a few RDC/TMD diagnoses (2 osteoarthritis and 6 disc displacements with reduction), and none of the patients was in need of TMD treatment, which was a criterion for exclusion. The low frequency of subjects with a clinical diagnosis of osteoarthritis (RDC/TMD IIIc; 4.8%) corresponds well with that reported by epidemiologic studies.²² However, the number of radiologic

bony changes was high. With only two clinical osteoarthritis diagnoses, it was surprising to find 21 TMJs with osteoarthritic bony alterations in the CBCT images while 51 of the TMJs were without indeterminate osteoarthritic radiographic changes.

Observer variation is common in diagnostic radiology. Nevertheless, an excellent interexaminer reliability has been reported when using well-defined criteria in evaluating CT images of the TMJ for the radiologic diagnosis of osteoarthritis.³ The two observers in the present study were calibrated using cross-sectional tomographic images, which are similar to CBCT images.⁶ Like CBCT, tomography has a low sensitivity and a high specificity for detecting TMJ osseous changes.^{23,24} To reduce the number of false-positive findings, the two examiners of this study followed the rule not to report dubious findings.

In the present study, the findings of subcortical cysts, surface erosion, osteophytes, or sclerosis were used as indicators for osteoarthritis, following the criteria for RDC/TMD, and 47.6% of the subjects had indeterminate osteoarthritic or osteoarthritic bony alterations.³ In another OSA investigation, 11% to 18% of the subjects had radiographic signs of degenerative joint disease or osteoarthritis of the TMJ as depicted by CBCT, and in line with the present findings, similar values (3% to 43%) for osteoarthritis radiologic changes were found in asymptomatic young adults with different types of skeletal malocclusion.^{13,25}

It may be questioned whether these radiographic findings are clinically relevant. In a study of asymptomatic persons without internal derangement, 35% of the TMJs showed flattening in the CT images.²⁶ The authors concluded that minimal flattening is probably without clinical significance. This is in accordance with autopsy studies showing that deviations in form of the condyle are common also in the absence of osteoarthritis.²⁷ The high frequencies of bony changes in the CBCT images of the pain-free subjects in the present study as well as in the study by Krisjane et al²⁸ indicate that radiographic signs of osteoarthritis are a poor indicator of pain. The same conclusion was reached by Falconet et al, who correlated radiographic bony changes in CBCT images with TMJ pain.¹² Similarly, radiographic signs of osteoarthritis are a poor indicator of the presence of knee pain or disability.²⁹ Future research may change the radiologic indicators for osteoarthritis. With the high frequency of osteoarthritic bony changes in pain-free TMJs, there is a risk of overtreatment in patients with TMD if the findings of the radiographic examination are not used critically and are not related to the pain reports and clinical findings. Therefore, CBCT imaging should not be used in isolation as the main basis for diagnosis of TMJ conditions, but when indicated it may support the clinical diagnosis and choice of treatment.

The median age of the subjects in the present study was 53 years. With a range from 26 to 73 years, age-related changes of the bony structures might have been present, and with an age-dependent frequency increase. However, the results did not support this hypothesis. In the present study, the most frequent type of bony deviation was flattening, which is typical of remodeling processes. As CBCT imaging was performed before the treatment with the intraoral appliance, it is impossible that the flattening was caused by the appliance.⁵ Moreover, remodeling in CBCT images has been reported even in young asymptomatic subjects.²⁸

Conclusions

A considerable proportion (47.6%) of OSA patients without ongoing pain and TMJ complaints had bony deviations in CBCT images. These bony changes were not associated with the clinical diagnoses.

Acknowledgments

This report is part of a study on obstructive sleep apnea and was supported by a strategic funding from the Department of Odontology, Faculty of Health and Medical Sciences, University of Copenhagen, Denmark. The authors declare no potential conflicts of interests with respect to the authorship and/or publication of this article.

References

1. LeResche L. Epidemiology of temporomandibular disorders: Implications for the investigation of etiologic factors. *Crit Rev Oral Biol Med* 1997;8:291–305.
2. Bakke M, Kjølner M. Kæbeledsbesvær – forekomst i den danske voksenbefolkning. *Tandlaeg Tidsskr* 1993;8:36–42.
3. Ahmad M, Hollender L, Anderson Q, et al. Research diagnostic criteria for temporomandibular disorders (RDC/TMD): Development of image analysis criteria and examiner reliability for image analysis. *Oral Surg Oral Med Oral Pathol Oral Radiol Endod* 2009;107:844–860.
4. Dworkin SF, LeResche L. Research diagnostic criteria for temporomandibular disorders: Review, criteria, examinations and specifications, critique. *J Craniomandib Disord* 1992;6:301–355.
5. Barghan S, Tetradis S, Mallya SM. Application of cone beam computed tomography for assessment of the temporomandibular joints. *Austr Dent J* 2012;57 (suppl 1):109–118.
6. Wiese M, Svensson P, Bakke M, et al. Association between temporomandibular joint symptoms, signs, and clinical diagnosis using the RDC/TMD and radiographic findings in temporomandibular joint tomograms. *J Orofac Pain* 2008;22:239–251.
7. Peck CC, Goulet JP, Lobbezoo F, et al. Expanding the Taxonomy of the Diagnostic Criteria for Temporomandibular Disorders (DC/TMD). *J Oral Rehabil* 2014;41:2–23.
8. Honey OB, Scarfe WC, Hilgers MJ, et al. Accuracy of cone-beam computed tomography imaging of the temporomandibular joint: Comparisons with panoramic radiology and linear tomography. *Am J Orthod Dentofacial Orthop* 2007;132:429–438.
9. Wiese M, Wenzel A, Hintze H, et al. Influence of cross-sectional temporomandibular joint tomography on diagnosis and management decisions of patients with temporomandibular joint disorders. *J Orofac Pain* 2011;25:223–231.
10. International RDC/TMD Consortium Network. <http://www.rdc-tmdinternational.org> [Accessed 19 August 2014].
11. Petersson A. What you can and cannot see in TMJ imaging – an overview related to the RDC/TMD diagnostic system. *J Oral Rehabil* 2010;37:771–778.
12. Falconet G, Ludlow JB, Tyndall DA, Lim PF. Correlating cone beam CT results with temporomandibular joint pain of osteoarthritic origin. *Dentomaxillofac Radiol* 2012;41:126–130.

13. Enciso R, Shigeta Y, Nguyen M, Clark GT. Comparison of cone-beam computed tomography incidental findings between patients with moderate/severe obstructive sleep apnea and mild obstructive sleep apnea/healthy patients. *Oral Surg Oral Med Oral Pathol Oral Radiol* 2012;114:373–381.
14. Alexiou KE, Stamatakis HC, Tsiklakis K. Evaluation of the severity of temporomandibular joint osteoarthritic changes related to age using cone beam computed tomography. *Dentomaxillofac Radiol* 2009;38:141–147.
15. dos Anjos Pontual ML, Freire JS, Barbosa JM, Frazao MA, dos Anjos Pontual A. Evaluation of bone changes in the temporomandibular joint using cone beam CT. *Dentomaxillofac Radiol* 2012;41:24–29.
16. Martinez-Gomis J, Willaert E, Nogue L, Pascual M, Somoza M, Monasterio C. Five years of sleep apnea treatment with a mandibular advancement device. Side effects and technical complications. *Angle Orthod* 2010;80:30–36.
17. Bakke M, Bergendal B, McAllister A, Sjögren L, Åsten P. Development and evaluation of a comprehensive screening for orofacial dysfunction. *Swed Dent J* 2007;31:75–84.
18. Sonnesen L, Bakke M, Solow B. Malocclusion traits and symptoms and signs of temporomandibular disorders in children with severe malocclusion. *Eur J Orthod* 1998;20:543–559.
19. Siersbæk-Nielsen S, Solow B. Intra- and interexaminer variability in head posture recorded by dental auxiliaries. *Am J Orthod* 1982;82:50–57.
20. Bakke M, Holm B, Jensen BL, Michler L, Möller E. Unilateral, isometric bite force in 8–68-year old women and men related to occlusal factors. *Scand J Dent Res* 1990;98:149–158.
21. Jordan AS, McSharry DG, Malhotra A. Adult obstructive sleep apnoea. *Lancet* 2014;383:736–747.
22. Manfredini D, Guarda-Nardini L, Wincour E, Piccotti F, Ahlberg J, Lobbezoo F. Research diagnostic criteria for temporomandibular disorders: A systematic review of axis I epidemiologic findings. *Oral Surg Oral Med Oral Pathol Oral Radiol Endod* 2011;112:453–462.
23. Look JO, Schiffman EL, Truelove EL, Ahmad M. Reliability and validity of Axis I of the Research Diagnostic Criteria for Temporomandibular Disorders (RDC/TMD) with proposed revisions. *J Oral Rehabil* 2010;37:744–759.
24. Rohlin M, Akerman S, Kopp S. Tomography as an aid to detect macroscopic changes of the temporomandibular joint. An autopsy study of the aged. *Acta Odontol Scand* 1986;44:131–140.
25. Hintze H, Wiese M, Wenzel A. Cone beam CT and conventional tomography for the detection of morphological temporomandibular joint changes. *Dentomaxillofac Radiol* 2007;36:192–197.
26. Brooks SL, Westesson PL, Eriksson L, Hansson LG, Barsotti JB. Prevalence of osseous changes in the temporomandibular joint of asymptomatic persons without internal derangement. *Oral Surg Oral Med Oral Pathol* 1992;73:118–122.
27. Hansson T, Öberg T. Arthrosis and deviation in form in the temporomandibular joint. A macroscopic study on a human autopsy material. *Acta Odontol Scand* 1977;35:167–174.
28. Krisjane Z, Urtane I, Krumina G, Neimane L, Ragovska I. The prevalence of TMJ osteoarthritis in asymptomatic patients with dentofacial deformities: A cone-beam CT study. *Int J Oral Maxillofac Surg* 2012;41:690–695.
29. Bedson J, Croft PR. The discordance between clinical and radiographic knee osteoarthritis: A systematic search and summary of the literature. *BMC Musculoskelet Disord* 2008;9:116.