

Ernest Syndrome: A Systematic Review of the Literature

Javiera Dominguez, DDS

Temporomandibular Disorder and
Orofacial Pain Program
Universidad de la Frontera
Temuco, Chile;
Dr Víctor Ríos Ruiz Healthcare Complex
Los Ángeles, Chile

Thomas Bornhardt, DDS, MSc

Department of Integral Adult Care
Dentistry
Temporomandibular Disorder and
Orofacial Pain Program
Sleep & Pain Research Group
Faculty of Dentistry
Universidad de La Frontera
Temuco, Chile

Schilin Wen, DDS

Doctoral Program in Morphological
Sciences
Sleep & Pain Research Group
Universidad de La Frontera
Temuco, Chile

Veronica Iturriaga, DDS, MSc, PhD

Department of Integral Adult Care
Dentistry
Temporomandibular Disorder and
Orofacial Pain Program
Sleep & Pain Research Group
Faculty of Dentistry
Universidad de La Frontera
Temuco, Chile

Correspondence to:

Prof Veronica Iturriaga
Department of Integral Adult Care
Faculty of Dentistry
Universidad de La Frontera
Avenida Francisco Salazar 01145
Temuco, Chile
Email: veronica.iturriaga@ufrontera.cl

Submitted June 12, 2019;
accepted October 11, 2019.
©2020 by Quintessence Publishing Co Inc.

Aims: To conduct a systematic review of the available evidence regarding the clinical characteristics and treatment of Ernest syndrome. **Methods:** A systematic search was carried out in the EBSCOhost, Embase, MEDLINE, ScienceDirect, Scopus, Web of Science, and Trip databases. The free terms "stylomandibular ligament" and "Ernest syndrome" were used, and the Boolean operator "OR" was used for connection of the terms. The research protocol was registered in PROSPERO (CRD42018112914). The results of this study are presented according to the PRISMA statement, and risk of bias was assessed according to the Quality Assessment Tool for Quantitative Studies of the Effective Public Health Practice Project. **Results:** A total of 57 articles were found, 5 of which met the selection criteria and were included in this review. The selected articles represent a population of 81 patients with primarily unilateral pain in the periauricular and mandibular areas. Diagnosis was established according to clinical history, recognition of pain on palpation of the mandibular angle, and remission following infiltration with local anesthesia. Concerning the treatments applied, infiltration with corticosteroids was highly successful, as was partial resection of the stylomandibular ligament and part of the styloid process. Furthermore, in refractory cases, the application of radiofrequency thermoneurolysis was described. **Conclusion:** The analyzed studies allow a better understanding of Ernest syndrome and the proposal of a tendinosis model for this condition. However, the evidence is scarce, and it is therefore necessary to carry out additional studies with better methodologic designs. *J Oral Facial Pain Headache 2020;34:167–173. doi: 10.11607/ofph.2551*

Keywords: Ernest syndrome, inflammation, pain, stylomandibular ligament, temporomandibular disorders

The temporomandibular joint (TMJ) is a synovial joint. Its main components are the mandibular condylar process, temporal bone, and articular disc, which are surrounded by a joint capsule, synovial membrane, and ligaments.¹ The ligaments are fibrous structures that allow the union of the joint surfaces and influence the joint dynamics. Some are capsular reinforcements while others are located a distance from the capsule; these are classified as main and accessory (extracapsular), respectively.² It is believed that the ligaments correspond to tendons or muscles that originally were in relation to the joint but over time took new insertions or lost their function; however, the primitive tendon near the joint persisted and became a ligament.³ It is also suggested that the function of the ligaments is to stabilize the joint by limiting movements, thereby protecting the more sensitive structures and acting as a guide in some movements.⁴ Ligaments, however, are subject to adaptive processes, which may be progressive or regressive. This progressive adaptation allows the ligament to lengthen and shorten according to the direction of the load, but a regressive adaptation process will generate inflammation with an inherent risk of ossification or rupture.⁵

The stylomandibular ligament (SL) is an accessory ligament of the TMJ with its origin in the styloid process near the apex and is inserted in the angle and posterior edge of the mandibular branch on its medial side.^{2,6}

Table 1 Search Strategies and Items (n) Identified and Selected in Each Database and Search Engine

Source	Search strategy	Search items	Selected by title and abstract	Selected by full text
EBSCOhost	"stylomandibular ligament" OR "ernest syndrome"	4	0	0
Embase	'stylomandibular ligament' OR 'ernest syndrome'	34	9	5
MEDLINE	("stylomandibular ligament") OR "ernest syndrome"	29	6	4
ScienceDirect	Title, abstract, keywords: "stylomandibular ligament" OR "ernest syndrome"	14	2	2
Scopus	(TITLE-ABS-KEY ("stylomandibular ligament") OR TITLE-ABS-KEY ("ernest syndrome"))	46	9	5
Web of Science	TOPIC: ("stylomandibular ligament") OR TOPIC: ("ernest syndrome")	20	5	4
Trip Database	"stylomandibular ligament" or "ernest syndrome" (primary research)	4	0	0

The styloid process is a cylindrical bony projection of 2 to 3 cm in length with an oblique antero-inferior trajectory, where the insertions of the stylohyoid ligament and the stylopharyngeal, stylohyoid, and styloglossus muscles are located.^{7–10}

There are different theories about the origin of the SL. Some authors postulate that the SL is a fibrous residue of a muscle bundle of the styloglossus muscle; another theory is that it is part of the cervical fascia or the deep fascia of the neck. In this scenario, the SL would present as a thickening of the parotid fascia or as an extension of the fascia of the medial pterygoid muscle, and this is part of the reason that the SL has been called a pseudo-ligament.^{3,11}

There seems to be no consensus regarding the function of the SL—some authors state that it limits protrusive movement and prevents excessive cranial rotation of the jaw, while other researchers indicate that it lacks function in mandibular dynamics.¹²

Temporomandibular disorders (TMD) are a set of functional alterations that affect the masticatory system.¹³ Alterations in most of the components of the masticatory system are described among the different classifications of TMD; however, the involvement of the SL is rarely described.^{14,15}

Ernest syndrome (ES) was first described in 1981 by Edwin A. Ernest and refers to inflammatory and painful irritation of the SL. Adequate descriptions of and information regarding the disease are scarce. Symptoms can manifest as pain in the angle of the jaw, radiate upwards toward the TMJ, and affect the ears and even the eyes. Symptoms are reproduced by palpation of the mandibular insertion of the SL.^{16,17}

The aim of this study was to conduct a systematic review of the available evidence regarding the clinical characteristics and treatment of ES.

Materials and Methods

Design and Protocol

A systematic review was carried out to answer the research question: What are the clinical charac-

teristics and treatment of ES? The research protocol was registered in PROSPERO with the number CRD42018112914. The results of this study are presented according to the PRISMA statement (Preferred Reporting Items for Systematic Reviews and Meta-Analyses).¹⁸ This article does not contain any study carried out on human subjects by any of the authors.

Eligibility Criteria and Outcomes

A search was carried out for primary articles describing the clinical characteristics and/or treatment of ES in human populations. The inclusion criteria were: Primary articles that evaluated the clinical and/or therapeutic characteristics of ES and studies of descriptive design or clinical trials, without limits on language or year of publication. Letters to the editor, reviews, congresses, and scientific posters were excluded. The main outcome was the identification of clinical characteristics and treatment of patients with ES. Other outcomes of interest were scientific characteristics of the primary studies (language, year of publication, and design of the article) and clinical variables (age and sex of the patients, time until the diagnosis was made, characteristics of the pain, possible etiologic causes, diagnostic criteria, differential diagnoses, and comorbidities).

Databases and Search Strategy

EBSCOhost, Embase, MEDLINE, ScienceDirect, Scopus, and Web of Science databases were used, as well as the Trip Database search engine. In the initial phase, a cursory search of the literature was performed to identify search terms, resulting in the terms: "stylomandibular ligament" (free term) and "Ernest syndrome" (free term). Subsequently, a sensitive search was carried out that added the Boolean operator "OR" and the limit "primary articles." The search was performed in January 2019 and was adapted to each database and its corresponding language. The MEDLINE search was ("stylomandibular ligament") OR "ernest syndrome". The search strategies for each database and search engine are detailed in Table 1.

Study Selection, Data Extraction, and Risk of Bias Assessment

The articles were analyzed independently by two researchers (V.I.; S.W.). In case of conflict, a third reviewer (T.B.) was consulted. First, the authors evaluated the articles by title, then by abstract, and finally by full-text reading. A filter was applied to eliminate duplicate items. For this process, the Mendely reference manager and the Covidence (Cochrane Collaboration) tool were used. The data were extracted manually in a Microsoft Excel spreadsheet for Mac (version 15.24, Microsoft), from which the subsequent analysis was carried out. The articles finally included were subjected to an evaluation of risk of bias according to the Quality Assessment Tool for Quantitative Studies of the Effective Public Health Practice Project (EPHPP),¹⁹ which has six components: selection bias, design, confounders, blinding, data collection methods, withdrawals, and dropouts. Each item was classified as having high, unclear, or low risk of bias, and a summary graph was made.

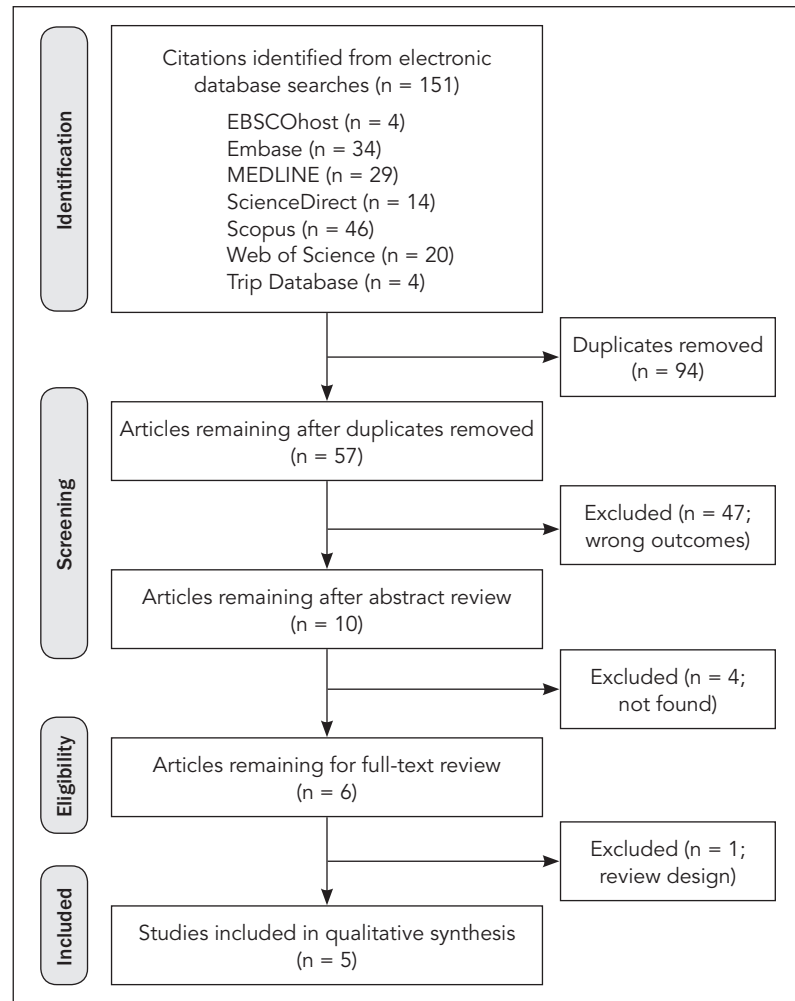


Fig 1 Flowchart of primary article selection according to the framework proposed by the PRISMA statement.¹⁸

Results

Search Results

In the search, 151 articles were found, with a final total of 57 articles after eliminating duplicates. Of these articles, 10 met the selection criteria when reviewing the titles and abstracts. However, it was not possible to access 4 of the articles since the authors were unavailable for contact, and these were therefore excluded. Of the remaining 6 articles, 5 met the selection criteria after full-text reading and were finally included in the analysis.^{17,20–23} The selection sequence is shown in Fig 1. Table 1 summarizes the details of article selection by database and search engine. Excluded articles can be seen in Appendix I (available in the online version only, at www.quintpub.com).

Scientific Characteristics of the Primary Studies

The selected articles were written in English^{20–23} and Spanish¹⁷ and were all observational studies. The publications of Shankland (1987),²¹ Wilk (1994),²² and Peñarrocha-Oltra et al (2013)¹⁷ are case series, Sataloff and Price (1984)²³ is a case report, and the Ernest article (1987)²⁰ is a report of two cases.

Clinical Characteristics

A total sample of 81 patients was obtained, with an age range between 13 and 69 years. The distribution according to sex, age, time between onset of symptoms and time of diagnosis, pain characteristics, and clinical characteristics are detailed in Table 2.

Regarding the diagnostic method for ES, most of the articles used the following criteria: history of pain in the specific anatomical region; pain on palpation of the mandibular insertion of the SL; and pain relief following the use of local anesthesia in the SL insertion area. Peñarrocha-Oltra et al¹⁷ also considered the absence of significant alterations in extraoral panoramic radiography as a diagnostic criterion.

In the Shankland study,²¹ comorbidity was mentioned with pathologies such as myofascial pain (39.7% of patients), internal TMJ

Table 2 Distribution of Patients According to Gender, Age, Time from Beginning of Symptomatology to Diagnosis, and Pain and Clinical Characteristics of Ernest Syndrome

Study (y)	Gender: no./age	Time to diagnosis	Pain characteristics	Clinical features
Sataloff and Price ²³ (1984)	F: 26 y	15 mo (after the initial surgery)	Retromandibular pain, sensitivity to deep palpation of the neck in the region of the styloid process and to palpation in the tonsillar fossa	Opening range decreased to 25% due to pain
Ernest ²⁰ (1987)	F: 29 y (A), 31 y (B)	A: 1 y B: 5 y	A: Chronic bilateral PA pain B: Nonspecific right hemifacial pain, greater severity in TMJ and PA; also at angle of the jaw, teeth, temporal, eye, and pharynx on the same side.	A: All mandibular ranges decreased and with pain according to the referred pain pattern of the ES B: Increased pain with protrusive movements and left laterality; pain with extension and left laterality of the head
Shankland ²¹ (1987)	F: 56 patients; M: 12 patients/ 13 to 69 y	4.37 y (0.08–26 y)	Bilateral (42.65%), right (32.35%), left (25%). Location: PA (88.24%); TMJ and temporal (85.29%); mandibular and dental (73.53%); pharyngeal (58.82%); ocular (55.88%), other (38.23%).	All mandibular ranges decreased
Wilk ²² (1994)	–	–	Pain in the auricular zone, TMJ, eye, zygomatic bone, posterior area of the jaw, molar teeth, and the neck in the area of the greater corner of the hyoid bone.	Traumatic injury precipitating factor in all patients
Peñarrocha-Oltra et al ¹⁷ (2013)	F: 6 patients/ 35 to 51 y	23 mo (6 mo–4 y)	Unilateral, deaf, continuous, ill-defined, slow onset, not triggered by any stimulus. Located in PA region and mandibular angle.	Absence of teeth in 5 patients, pain in the masseter and pain in the masseter and medial pterygoid of the affected side in 2 cases; all with asymptomatic TMJ

F = female; M = male; PA = periauricular, ES = Ernest syndrome.

disorders (38.24%), tendonitis of the temporal muscle tendon (16.2%), and occipital neuralgia (10.3%). Likewise, Sataloff and Price²³ suggest as differential diagnoses of ES—among a number of other pathologies—TMJ disorders, glossopharyngeal neuralgia, odontogenic pain, chronic tonsillitis, cervical arthritis, and spinal palatine ganglion neuralgia.

Regarding the etiology of ES, the studies reviewed suggest a prior event of various causes at the onset of symptoms. The majority of such events were related to trauma. Ernest²⁰ describes the presence of an automobile accident as an etiologic factor in both reported cases. Shankland²¹ cataloged them as being of unknown etiology in 41.2% of cases, following a car accident in 32.4%, mandibular trauma in 16.2%, and associated with medical or dental iatrogenesis in 4% of patients. Peñarrocha-Oltra et al¹⁷ identified the onset of pain after episodes of forced mandibular opening due to endodontic dental procedures or tooth extraction in four of the six patients. Sataloff and Price²³ described the onset of pain 15 months after mandibular osteotomy surgery due to

dentoskeletal malocclusion. The probable causes are not described in the Wilk article.²²

The articles describe three therapeutic options that were applied following different protocols. These are peri-ligamentous infiltration with corticosteroids, application of radiofrequency thermoneurolysis, and division of the SL and part of the styloid process. The procedures and their results are described in Table 3.

Risk of Bias

The five selected studies presented a high risk of global bias. Figure 2 details the risk of bias according to author and item evaluated.

Discussion

ES, first described in 1981 by Edwin A. Ernest, is defined as inflammatory and painful irritation of the SL. This pathology is scarcely described, but is of significant interest in the diagnosis of orofacial pain, namely for its high comorbidity with other painful pathologies

Table 3 Treatments Applied for the Management of Ernest Syndrome and Their Results

Study (y)	Treatment	Results
Sataloff and Price ²³ (1984)	The stylomandibular ligament was sectioned, and 1 cm of the distal region of the styloid process was extracted.	Immediate improvement on the first postoperative day: Noticeable decrease in pain and normal jaw excursion. Follow-up at 18 months showed no recurrence of pain.
Ernest ²⁰ (1987)	A: Nonsurgical: Infiltration of 0.25 cc of cortisone in the SL insertion. B: Nonsurgical and surgical: Three sessions of cortisone infiltration with total but temporary remission of pain, which is why radiofrequency thermoneurolysis was performed.	A: After 3 years of control, the patient remains asymptomatic. B: Asymptomatic at 1 year of follow-up.
Shankland ²¹ (1987)	Nonsurgical: Anesthetic block, injection of 1 cc of betamethasone sodium phosphate, and soft diet. Surgical: Radiofrequency thermoneurolysis under local anesthesia and guided with fluoroscopy.	Successful nonsurgical treatment in 77.94% of patients. Some cases received repeated treatment, up to 4 times at 2-week intervals. Surgical treatment was performed in 22.06% of patients. No information regarding follow-up.
Wilk ²² (1994)	Surgical: Radiofrequency thermolysis in the temporal tendon under local anesthesia and guided with fluoroscopy.	100% effectiveness in patients at 18 months of follow-up (asymptomatic).
Peñarrocha-Oltra ¹⁷ (2013)	Infiltration of 40 mg of triamcinolone acetonide in the SL insertion. Restoration of occlusion with prostheses (4 RPDs and 1 FP), mandibular rest, and soft diet for 15 days. In 2 cases of persistent symptomatology, the infiltration was repeated 15 days later.	Follow-up for 1 year. Four patients had complete pain remission, and two required a repeat procedure. At 1 year of follow-up, 100% had complete resolution of pain.

SL = stylomandibular ligament; RPD = removable partial denture; FP = fixed prosthesis.

in the region. From a physiopathologic point of view, it can be mentioned that Ernest describes it with the “insertion tendinosis” model. The process is similar to tendinitis/tendinosis of the temporal muscle tendon.^{20,24} This model proposes that when subjected to the functional or traumatic forces that generate a change in the direction of the ligament, it is the uncalcified cartilage that absorbs the tensile or compressive energy, depending on the direction of the force. This could explain why ES presents a high level of inflammatory pain even though the SL is a poorly perfused structure.

Clinically, ES is presented in two stages during its evolution. In the initial stage, infra-auricular and jaw tenderness are described near the mandibular angle.¹⁷ In a later stage, pain can be found in the TMJ, orbital and temporal areas, oropharynx, and coronoid process, as well as odontalgia in the posteroinferior teeth.^{17,20}

The studies analyzed in the present work confirm that other authors are in agreement with the progression and stages of the disease, which contributes to the data regarding its clinical overview. These data usually relate a history of painful trauma in the mandibular area, a greater predilection for being unilateral, and were found located in the periauricular area or angle of the jaw.^{17,21,23} Due to the high comorbidity with painful diseases, the authors of the studies analyzed

	Selection bias	Study design	Confounders	Blinding	Data collection methods	Withdrawals and drop-outs
Peñarrocha-Oltra ¹⁷ et al (2013)	–	?	–	–	–	+
Ernest ²⁰ (1986)	–	?	–	–	–	–
Shankland ²¹ (1984)	–	?	–	–	–	?
Wilk ²² (1994)	–	?	–	–	–	+
Sataloff ²³ (1984)	–	–	–	–	–	+

Fig 2 Risk of bias summary according to the Quality Assessment Tool for Quantitative Studies of the Effective Public Health Practice Project (EPHPP).¹⁹ Red – = high risk of bias; yellow ? = unclear risk of bias; green + = low risk of bias.

agree that the fundamental diagnostic criterion is the reproduction of pain on palpation in the mandibular angle and the subsequent remission of symptoms with the infiltration of local anesthetic in the same area.

It is important to mention that both the clinical characteristics and physiopathologic processes can be described better under the tendinosis model—specifically as tendinosis of the SL—presenting an inflammatory, progressive, and intrinsic and/or extrinsic etiology that triggers pain and functional alterations. Nevertheless, no studies were found that assess the presence or absence of intrinsic factors that may be occurring in the pathology. When analyzing the symptomatology and high comorbidities of ES, it is important to rule out the presence of other orofacial pathologies that define the symptoms, as well as the need to consider these within the diagnostic criteria.

Eagle syndrome is a similar condition; however, its pathogenesis includes calcification processes, and there is no evidence that this phenomenon occurs in ES. This could be due to the overprojection of the possibly calcified area (area of SL insertion) with the body and branch of the jaw, which makes the analysis more complex in planar radiographs. There are reports of calcifications distal to the angle of the mandible, but Goldstein and Scopp (1973) clarify that these calcifications correspond more to Eagle's syndrome than to ES.^{2,25} In relation to the above, Sataloff and Price²³ mention that despite their recommendation to use radiography, a normal result should not rule out the existence of ES. The use of 3D imaging to eliminate the problem of overlap is not mentioned in the reviewed articles, and there are no reports on the use of advanced imaging techniques for the location of inflammatory changes, such as magnetic resonance imaging or computed tomography, which from a theoretical point of view seem to be useful forms of diagnostic approach.

Differential diagnosis for ES is complex. No pathognomonic factors of ES have been reported; however, when there is suspicion, a careful history, physical examination, radiographs, and, in selective cases, laboratory studies usually make the diagnosis relatively straightforward.²³ In this context, it has been described that when this ligament is stretched more than 25 to 30 mm, it can cause cervical and pharyngeal pain, as well as pain when swallowing, speaking, and opening the mouth, with a sensation of a foreign body in the oropharynx and pain radiating to the ear.¹⁷

It has also been suggested that prolonged dental treatments could cause elongation and distension of the SL, resulting in painful symptomatology,²¹ which was confirmed in Peñarrocha-Oltra et al.¹⁷ Shankland²¹ observed that more than 50% of examined patients reported a traumatic episode as a precipitating cause of their pain, as Ernest²⁰ confirmed previously. Even Wilk²² observed that 100% of patients reported a traumatic incident of either an automobile accident involving a flexion-extension injury or a direct cranial impact preceding the onset of

symptomatology. In addition, flexion-extension injuries such as those in whiplash are known to cause symptoms similar to those of ES.²¹

With respect to treatment, there are three therapies mainly reported. The therapy most used in the evidence is the infiltration of corticosteroids from the area of the SL insertion. This treatment supports its theoretical validity in the resolution of the pathophysiologic inflammatory process generated by the tendinosis process. The infiltration is done before local anesthesia, and later palliative measures are established, such as the use of analgesics, anti-inflammatories, local heat, and soft diet. The use of three substances is reported: Peñarrocha-Oltra¹⁷ et al used 40 mg of triamcinolone acetonide, Shankland²¹ utilized 1 cc of betamethasone sodium phosphate, and Ernest²⁰ used 0.25 cc of synthetic cortisone. In the Peñarrocha-Oltra et al¹⁷ and Ernest²⁰ protocols, a 100% improvement was achieved, and in the Shankland²¹ protocol, a 77.9% improvement was achieved. It is described that in cases where there is no response to the corticosteroid infiltration therapy, radiofrequency thermoneurolysis can be useful, generating a lesion that in turn causes a sensitive denervation of the area where the tendinosis is located. It is recommended that the procedure be performed with fluoroscopy to determine location of the needle, and total remission has been achieved with this technique.^{20,26} This procedure has traditionally been used to treat pain disorders of differing etiologies, primarily in the low back and cervical areas. Wilk²² described 100% effectiveness of therapy by radiofrequency thermolysis in patients with ES.

Surgery is a third option, and its success has been reported without recurrence of symptoms. In this procedure, division of the SL and 1-cm resection of the distal end of the styloid process are performed, and immediate improvement of the symptomatology and a recovery of the ranges of motion are reported.²³

Limitations

The limitations of the present study are mainly related to the scarce information on the subject and its low quality. Therefore, these results should be considered carefully. In addition, it was not possible to perform a meta-analysis due to the heterogeneity of the data found and the designs of the studies included.

Conclusions

ES has a poorly described pathology that corresponds to the tendonitis/tendonosis model, similar to that which occurs in tendonitis of the temporal muscle tendon. Clinically, it manifests as unilateral pain of slow onset that is dull, continuous, and poorly

defined. It can be located in the retromandibular, periauricular, TMJ, teeth, temporal, zygomatic bone, eye, and pharynx areas on the same side, with sensitivity to deep palpation of the neck in the region of the styloid process and tonsillar fossa. Therefore, in patients with these clinical manifestations, it should be considered that anesthetic block in the mandibular angle with subsequent remission of the symptomatology is currently the diagnostic criterion unanimously applied.

ES presents a high occurrence of comorbidity with other painful pathologies in the region; thus, differential diagnosis is fundamental. Regarding treatment, infiltration with peri-ligament corticosteroids seems to be a simple and uncomplicated procedure that may provide significant symptomatic relief. Although the studies analyzed allow for a better understanding of ES, the evidence available is scarce, heterogeneous, and of poor quality, so it is necessary to generate further information, specifically by improving sample sizes and the quality of the evidence.

Acknowledgments

This research was supported by CONICYT through the National Doctoral Fellowship (CONICYT, PFCHA/ Doctorado Nacional/2015-21151352). The authors wish to thank the Temporomandibular Disorders and Orofacial Pain Program from Universidad de La Frontera for the support in the translation of the article. The authors report no conflicts of interest.

References

- Okeson JP (ed). *Management of Temporomandibular Disorders and Occlusion*, ed 7. St. Louis: Mosby, 2012.
- Goldstein GR, Scopp IW. Radiographic interpretation of calcified stylomandibular and stylohyoid ligaments. *J Prosthet Dent* 1973;30:330–334.
- Fuentes R, Ottone N, Cantin M, Bucchi C. Análisis de los términos utilizados en la literatura científica para referirse a los ligamentos extracapsulares de la articulación temporomandibular: Parte II: Ligamentum stylomandibulare y raphe pterygoidale. *Int J Morphol* 2014;32:1289–1295.
- Bumann A, Lotzmann U. TMJ Disorders and orofacial pain. The role of dentistry in a multidisciplinary diagnostic approach. In: Rateitschak KH, Wolf HF (ed). *Color Atlas of Dental Medicine*. Thieme, 2002.
- De Paz FJ, Rueda C, Barbosa M, García M, Pastor JF. Biometry and statistical analysis of the styloid process. *Anat Rec (Hoboken)* 2012;295:742–747.
- Shivakumar HR, Batra J, Upasi AP, Rai KK. Evaluation of elongated styloid process in patients with oral submucous fibrosis using panoramic radiographs. *J Maxillofac Oral Surg* 2014;13:556–559.
- Lavine MH, Stoopack JC, Jerrold TL. Calcification of the stylohyoid ligament. *Oral Surg Oral Med Oral Pathol* 1968;25:55–58.
- Naik SM, Naik SS. Tonsillo-styloideotomy for Eagle's syndrome: A review of 15 cases in KVG Medical College Sullia. *Oman Med J* 2011;26:122–126.
- Mupparapu M, Robinson MD. The mineralized and elongated styloid process: A review of current diagnostic criteria and evaluation strategies. *Gen Dent* 2005;53:54–59.
- Patil S, Ghosh S, Vasudeva N. Morphometric study of the styloid process of temporal bone. *J Clin Diagn Res* 2014;8:AC04–AC06.
- Janfaza P. *Surgical Anatomy of the Head and Neck*. Cambridge, MA: Harvard University, 2011.
- Beukes J, Reyneke JP, Becker PJ. Medial pterygoid muscle and stylomandibular ligament: The effects on postoperative stability. *Int J Oral Maxillofac Surg* 2013;42:43–48.
- Dimitroulis G. Temporomandibular disorders: A clinical update. *BMJ* 1998;317:190–194.
- Schiffman E, Ohrbach R, Truelove E, et al. Diagnostic Criteria for Temporomandibular Disorders (DC/TMD) for clinical and research applications: Recommendations of the International RDC/TMD Consortium Network and Orofacial Pain Special Interest Group. *J Oral Facial Pain Headache* 2014;28:6–27.
- Peck CC, Goulet JP, Lobbezoo F, et al. Expanding the taxonomy of the diagnostic criteria for temporomandibular disorders. *J Oral Rehabil* 2014;41:2–23.
- Shankland WE. Anterior throat pain syndromes: Causes for undiagnosed craniofacial pain. *Cranio* 2010;28:50–59.
- Peñarrocha-Oltra D, Ata-Ali J, Ata-Ali F, Peñarrocha-Diogo MA, Peñarrocha M. Treatment of orofacial pain in patients with stylomandibular ligament syndrome (Ernest syndrome). *Neurologia* 2013;28:294–298.
- Moher D, Liberati A, Tetzlaff J, Altman DG, PRISMA Group. Preferred Reporting Items for Systematic Reviews and Meta-Analyses: The PRISMA Statement. *PLoS Med* 2009;6:e1000097.
- Thomas BH, Ciliska D, Dobbins M, Micucci S. A process for systematically reviewing the literature: Providing the research evidence for public health nursing interventions. *Worldviews Evid Based Nurs* 2004;1:176–184.
- Ernest EA. The Ernest syndrome: An insertion tendinosis of the stylomandibular ligament. *J Neuro Orthop Med Surg* 1987;7:427–438.
- Shankland WE. Ernest syndrome as a consequence of stylomandibular ligament injury: A report of 68 patients. *J Prosthet Dent* 1987;57:501–506.
- Wilk SJ. Surgical management of refractory craniomandibular pain using radiofrequency thermolysis: A report of thirty patients. *Cranio* 1994;12:93–99.
- Sataloff RT, Price DB. Distention of the stylomandibular ligament as a cause of styloid pain syndrome. *Ear Nose Throat J* 1984;63:412–415.
- Ernest EA 3rd, Martinez ME, Rydzewski DB, Salter EG. Photomicrographic evidence of insertion tendinosis: The etiologic factor in pain for temporal tendonitis. *J Prosthet Dent* 1991;65:127–131.
- Thoma KH. Case report no. 41. Calcification of the stylomandibular ligament. *Am J Orthod Oral Surg* 1940;26:812.
- López-Rodríguez MA, Varela M, Camba MA. Aplicaciones de la radiografía en el tratamiento del dolor crónico benigno. Una revisión de las publicaciones de los últimos 6 años. *Rev Soc Esp Dolor* 2001;8:397–411.

Appendix I Excluded Articles

1. DuPont JS Jr, Brown CE. Provocation testing to assist craniomandibular pain diagnosis. *Cranio* 2010;28:92–96.
2. Shankland WE 2nd. Anterior throat pain syndromes: Causes for undiagnosed craniofacial pain. *Cranio* 2010;28:50–59.
3. Cezairli B, Sivrikaya EC, Omezli MM, Ayranci F, Seyhan Cezairli N. Results of combined, single-session arthrocentesis and dextrose prolotherapy for symptomatic temporomandibular joint syndrome: A case series. *J Altern Complement Med* 2017;23:771–777.
4. Sukegawa S, Kanno T, Yoshimoto A, et al. Use of an intraoperative navigation system and piezoelectric surgery for styloidec-tomy in a patient with Eagle's syndrome: A case report. *J Med Case Rep* 2017;11:322.
5. Wang J, Li H, Zong S, et al. The influences upon the passive tensile of the masticatory muscles and ligaments by twin-block appliance under various bite reconstruction [in Chinese]. *Hua Xi Kou Qiang Yi Xue Za Zhi* 2013;31:172–177.
6. Baharudin A, Rohaida I, Khairudin A. Transoral surgical resection of bilateral styloid processes elongation (Eagle's syndrome). *Acta Inform Med* 2012;20:133–135.
7. Ribeiro A, Keat R, Khalid S, et al. Prevalence of calcifications in soft tissues visible on a dental pantomogram: A retrospective analysis. *J Stomatol Oral Maxillofac Surg* 2018;119:369–374.
8. Aymach Z, Kawamura H. Facilitating ramus lengthening following mandibular-dependent surgical closing of a skeletal open bite with short ramus: A new modified technique. *J Craniomaxillofac Surg* 2012;40:169–172.
9. Correll RW, Wescott WB. Eagle's syndrome diagnosed after history of headache, dysphagia, otalgia, and limited neck movement. *J Am Dent Assoc* 1982;104:491–492.
10. Wong E, Lee G, Mason DT. Temporal headaches and associated symptoms relating to the styloid process and its attachments. *Ann Acad Med Singapore* 1995;24:124–128.
11. Shereen R, Gardner B, Altafulla J, et al. Pediatric glossopharyngeal neuralgia: A comprehensive review. *Childs Nerv Syst* 2019;35:395–402.
12. Cömert Kiliç S, Güngörmüş M. Assessment of long term effectiveness of dextrose prolotherapy in subjects with temporomandibular hypermobility. *Osteoporosis International* 2015;26 (suppl 1):s364.
13. Kiralj A, Illić M, Pejaković B, Markov B, Mijatov S, Mijatov I. Eagle's syndrome—A report of two cases. *Vojnosanit Pregl* 2015;72:458–462.
14. Beukes J, Reyneke JP, Becker PJ. Medial pterygoid muscle and stylomandibular ligament: The effects on postoperative stability. *Int J Oral Maxillofac Surg* 2013;42:43–48.
15. Orabi AA, Riad MA, O'Regan MB. Stylomandibular tenotomy in the transcervical removal of large benign parapharyngeal tumours. *Br J Oral Maxillofac Surg* 2002;40:313–316.
16. Song J, Zhao Z, Hu L, Jiang W, Fan Y, Chen J. The influences upon the passive tensile of the masticatory muscles and ligaments by Herbst appliance under various bite reconstruction—A three dimensional finite element analysis [in Chinese]. *Hua Xi Kou Qiang Yi Xue Za Zhi* 2001;19:43–45.
17. Shankland WE 2nd. Common causes of nondental facial pain. *Gen Dent* 1997;45:246–253.
18. Brown CR. Ernest syndrome: Insertion tendinosis of the stylomandibular ligament. *Pract Periodontics Aesthet Dent* 1996; 8:762.
19. Shimada K, Gasser RF. Morphology of the mandibulo-stylohyoid ligament in human adults. *Anat Rec* 1988;222:207–210.
20. Shankland WE. Ernest syndrome (insertion tendinosis of the stylomandibular ligament) as a cause of craniomandibular pain diagnosis, treatment and report of two patients. *J Neurol Ortho Med Surg* 1987;8:253–257.
21. Ernest EA. Three disorders that frequently cause temporomandibular joint (TMJ) pain: Internal derangement, temporal tendinitis, and Ernest syndrome. *J Neurol Orthop Surg* 1986;7: 789–791.
22. Sataloff RT, Price DB. Mandibular osteotomy complicated by styloid pain. *Oral Surg Oral Med Oral Pathol* 1983;56:25–28.
23. Correll RW, Jensen JL, Taylor JB, Rhyne RR. Mineralization of the stylohyoid-stylomandibular ligament complex. A radiographic incidence study. *Oral Surg Oral Med Oral Pathol* 1979;48:286–291.
24. Hilloowala RA. Comparative anatomical study of the hyoid apparatus in selected primates. *Am J Anat* 1975;142:367–384.
25. Goldstein GR, Scopp IW. Radiographic interpretation of calcified stylomandibular and stylohyoid ligaments. *J Prosthet Dent* 1973;30:330–334.
26. Fay JT, Schow SR. Bilateral stylomandibular ligament calcification. *Oral Surg Oral Med Oral Pathol* 1969;27:759.
27. Melcherson I. The styloid process and the stylomandibular ligament; anatomical findings [in Swedish]. *Sven Lakartidn* 1955; 52:2981–2984.
28. Matsumoto F, Kase K, Kasai M, Komatsu H, Okizaki T, Ikeda K. Endoscopy-assisted transoral resection of the styloid process in Eagle's syndrome. Case report. *Head Face Med* 2012;8:21.
29. de Souza Carvalho AC, Magro Filho O, Garcia IR Jr, de Holanda ME, de Menezes JM Jr. Intraoral approach for surgical treatment of Eagle syndrome. *Br J Oral Maxillofac Surg* 2009;47:153–154.
30. Shivakumar HR, Batra J, Upasi AP, Rai KK. Evaluation of elongated styloid process in patients with oral submucous fibrosis using panoramic radiographs. *J Maxillofac Oral Surg* 2014;13:556–559.
31. Shiba Y, Matsuyama F, Horii M, Taniguchi S, Mizojiri G. Four cases of parapharyngeal mixed tumors originating in the parotid gland. *Practica Oto-Rhino-Laryngologica* 1963;76: 2521–2527.
32. Burch JG. Activity of the accessory ligaments of the temporomandibular joint. *J Prosthet Dent* 1970;24:621–628.
33. Romero GJ, Nieto Mungia AM, Sánchez Amador AR. Síndrome de Eagle. Manejo del paciente en el Hospital Regional. *Revista Odontológica Mexicana* 2015;19:258–262.
34. Jebblaoui Y, Tulasne JF. The sphenomandibular ligament: An anatomical obstacle to ramus lengthening. *Rev Stomatol Chir Maxillofac* 2011;112:365–368.
35. Aymach Z, Kawamura H. Facilitating ramus lengthening following mandibular-dependent surgical closing of a skeletal open bite with short ramus: A new modified technique. *J Craniomaxillofac Surg* 2012;40:169–172.
36. Kaufman SM, Elzay RP, Irish EF. Styloid process variation. Radiologic and clinical study. *Arch Otolaryngol* 1970;91:460–463.
37. Keller JH, Moffett BC Jr. Nerve endings in the temporomandibular joint of the Rhesus Macaque. *Anat Rec* 1968;160: 587–594.
38. Work WP, Habel DW. LXI Mixed tumors of the parotid gland with extension to the lateral pharyngeal space. *Annals of Otolaryngology & Laryngology* 1963;72:842–860.
39. Dos Santos CC, de Amorim AA, de Oliveira BP, de Melo Silva EM, Soares Torres RC. Variation of length of styloid process. *Int J Morphol* 2010;28:1277–1280.

40. Piagkou M, Anagnostopoulou S, Kouladourous K, Piagkos G. Eagle's syndrome: A review of the literature. *Clin Anat* 2009; 22:545–558.
41. Beder E, Ozgursoy OB, Karatayli Ozgursoy S, Anadolu Y. Three-dimensional computed tomography and surgical treatment for Eagle's syndrome. *Ear Nose Throat J* 2006; 85:443–445.
42. Itoh KI, Murakami H, Hayashi, T. Functions of ligaments during jaw open-close movement—An analysis using a two-dimensional dynamic model. *Proceedings of the Second Joint 24th Annual Conference and the Annual Fall Meeting of the Biomedical Engineering Society. Engineering in Medicine and Biology* 2002;3:2565–2566.
43. Shankland WE 2nd. Bursitis of the hamular process. Part I: Anatomical and histological evidence. *Cranio* 1996; 14:186–189.
44. Hirazawa M, Murata K, Oiki H, Ohta F. Extirpation of a dumbbell tumor of the parotid gland through a skin incision. *Practica Oto-Rhino-Laryngologica* 1993;86:225–228.
45. Fuentes R, Ottone N, Cantin M, Bucchi C. Analysis of terms used in scientific literature referred to extracapsular ligaments of the temporomandibular joint: Part II: Ligamentum stylomandibulare and raphe pterymandibulare. *Int J Morphol* 2014;32:1289–1295.
46. Nedunchezian K. Eagle syndrome—An overview. *SA Journal of Radiology* 2017;21:a1247.
47. Singh B, Purohit JP, Kashyap SK, Bhan C, Siva S. Lateral neck pain—Eagle's Syndrome: A report of two cases. *International Journal of Scientific Study* 2015;3(7):266–269.
48. Palesy P, Murray GM, De Boever J, Klineberg I. The involvement of the styloid process in head and neck pain: A preliminary study. *J Oral Rehabil* 2000;27:275–287.
49. Montalbetti L, Ferrandi D, Pergami P, Savoldi F. Elongated styloid process and Eagle's syndrome. *Cephalalgia* 1995; 15:80–93.
50. Shankland WE 2nd. Ernest syndrome (stretch injury of the stylomandibular ligament)—A study of 68 patients. *Headache* 1988;28:305.
51. Jasso G, Munguía AM, Amador A. Eagle's syndrome. Patient handling at the «Licenciado Adolfo López Mateos» Hospital Mexico City. *Revista Odontológica Mexicana* 2015; 19:e254–e258.
52. Jasso G, Munguía AM, Amador A. Síndrome de Eagle. Manejo del paciente en el Hospital Regional «Licenciado Adolfo López Mateos». *Revista Odontológica Mexicana* 2015;19:258–262.